

# *Demodex* in ophthalmology

OVERVIEW OF THE LATEST EVIDENCE





# AUTHORS

---

**Altan OZCAN**

*Department of Ophthalmology, Cukurova University, School of Medicine, Adana, Turkey*

**Jesús MERAYO**

*Department of Ophthalmology, University of Oviedo, Spain*

**Nikos MARKOMICHELAKIS**

*Institute of Ocular Inflammation and Pathology of the Eye, Athens, Greece*

**Semira KAYA**

*Hietzing hospital, Vienna, Austria*

**Serge DOAN**

*Department of Ophthalmology, Bichat Hospital and Fondation A de Rothschild, Paris, France*

**Sihem LAZREG**

*Alger, Algeria*

**Teifi JAMES**

*FRCP FRCS FRCOph, Consultant Ophthalmologist and Ophthalmic Surgeon, Calderdale Royal Hospital, West Yorkshire, UK*



## **Professor Christophe BAUDOUIN**

Department of Ophthalmology III,  
15-20 National Ophthalmology Hospital  
Institut de la Vision - (IHU) FOrReSIGHT - Paris, France



# PREFACE

---

Since Coston described *Demodex* associated with blepharitis in 1967 there has been heated debate about the role of the *Demodex* mite. The key question remains, is the mite a commensal organism or is it pathogenic? It seems that dermatologists are now convinced that *Demodex* is a pathogenic factor in the development of rosacea. Recently, many eye care professionals have been open to the possibility that the cylindrical dandruff which surrounds the root of the eyelashes, where they emerge from the piliferous eyelid skin, arises as a consequence of *Demodex* infestation of the eyelash follicles. Several mechanisms of inflammation have been postulated, including mechanical irritation, hypersensitivity and inflammation caused by bacteria which colonise the *Demodex* mites. It is unclear whether *Demodex* mites cause blepharitis in every host or indeed why some people react differently to *Demodex* infestation. There are several unanswered questions that the eye care community still has to address; is the dramatic severe blepharitis and tarsal plate inflammation presenting in infants and young children a manifestation of an initial infestation? Is a chalazion simply a host response to dead or dying *Demodex* mites releasing pro-inflammatory material? And what is the most appropriate way to manage *Demodex* infestation? New technologies such as confocal microscopy have made accessible *Demodex* infestation to the clinician, not only in eyelashes but also in meibomian glands, which raises new hypotheses regarding its related pathologies. Meibomian gland dysfunction also has major impact on tear film instability and dry eye disease. From the chicken or the egg, many unsolved questions remain and make this review a valuable step in the *Demodex* story.



# ABBREVIATIONS LIST

---

<b>BKC:</b>	BlepharoKeratoConjunctivitis
<b>DED:</b>	Dry Eye Disease
<b>IL:</b>	InterLeukin
<b>IVCM:</b>	<i>In Vivo</i> Confocal Microscopy
<b>MGD:</b>	Meibomian Gland Dysfunction
<b>MUC5AC:</b>	MUCin 5AC
<b>OR:</b>	Odds Ratio
<b>OSDI:</b>	Ocular Surface Disease Index
<b>PGE2:</b>	ProstaGlandin E2
<b>RCM:</b>	Reflectance Confocal Microscopy
<b>SSSB:</b>	Standard Skin Surface Biopsy
<b>TNF:</b>	Tumor Necrosis Factor
<b>TTO:</b>	Tea Tree Oil
<b>T4O:</b>	Terpinen-4-Ol
<b>UODS:</b>	Uludag Ocular Demodicosis clinical Scoring



# TABLE OF CONTENT

<b>1. INTRODUCTION .....</b>	<b>13</b>
1.1 <i>DEMODEX</i> BACKGROUND AND EPIDEMIOLOGY ASPECTS .....	15
1.2 THE LIFE CYCLE OF <i>DEMODEX</i> MITES.....	18
1.3 PREVALENCE OF <i>DEMODEX</i> IN HUMANS.....	19
1.4 PREVALENCE OF OCULAR <i>DEMODEX</i> .....	20
1.5 <i>DEMODEX</i> IN THE PATHOGENESIS OF SKIN DISEASE .....	22
1.6 <i>DEMODEX</i> IN THE PATHOGENESIS OF EYE DISEASE .....	23
<b>2. DEMODEX BLEPHARITIS.....</b>	<b>27</b>
2.1 RISK FACTORS AND COMORBIDITIES IN <i>DEMODEX</i> BLEPHARITIS.....	30
2.2 CLINICAL PRESENTATION OF <i>DEMODEX</i> BLEPHARITIS .....	31
2.2.1 SYMPTOMS	
2.2.2 CLINICAL SIGNS	
2.2.3 COMPLICATIONS IN <i>DEMODEX</i> BLEPHARITIS	
<b>3. DIAGNOSING <i>DEMODEX</i> INFESTATION IN OPHTHALMOLOGY .....</b>	<b>35</b>
3.1 LASH SAMPLING/EPIRATION AND MICROSCOPIC EVALUATION .....	36
3.2 LASH ROTATION/TRACTION AND LIGHT MICROSCOPY.....	37
3.3 <i>IN VIVO</i> CONFOCAL MICROSCOPY (IVCM).....	38
3.4 SPONTANEOUS FLUORESCENCE.....	39
3.5 CLINICAL SCORING .....	40
3.6 <i>DEMODEX</i> DIAGNOSIS IN PRACTICE .....	40
<b>4. TREATING <i>DEMODEX</i> IN OPHTHALMOLOGY .....</b>	<b>43</b>
4.1 SYSTEMIC TREATMENTS.....	44
4.2 TOPICAL TREATMENTS.....	46
4.2.1 LID HYGIENE	
4.2.2 TOPICAL TREATMENT CONTAINING ACTIVE SUBSTANCES	
4.3 SHOULD WE AIM FOR TOTAL ERADICATION?.....	56
<b>5. WHO TO TREAT, AND WHEN? .....</b>	<b>59</b>
<b>6. CLINICAL FAQs HANDY REFERENCE GUIDE.....</b>	<b>63</b>



# LIST OF FIGURES AND TABLES

Figure 1: Pubmed publications count from 1947 to April 2018.....	14
Figure 2: <i>Demodex folliculorum</i> and <i>Demodex brevis</i> .....	15
Figure 3: <i>Demodex</i> positioning in eyelash follicles (reproduced by permission of David Crystal) .....	16
Figure 4: <i>Demodex</i> anatomy .....	17
Figure 5: Eyelid in vivo confocal microscopy. Adult forms of <i>Demodex</i> (arrows) (from Morkin & Hamrah 2016) .....	17
Figure 6: <i>Demodex folliculorum</i> life cycle .....	18
Figure 7: Importance of meibomian gland dysfunction in the vicious circle of the pathology of dry eye disease (adapted from Baudouin 2016). .....	24
Figure 8: Ocular signs caused by <i>Demodex</i> infestation .....	31
Figure 9: Collarettes (cylindrical dandruff) .....	32
Figure 10: <i>Demodex</i> under optical microscopy with methylene blue (from Canti 2010) .....	37
Figure 11: Lash rotation (from Mastrotta 2013).....	37
Figure 12: Lateral Eyelash Traction .....	38
Figure 13: Eyelid in vivo confocal microscopy. Adult forms of <i>Demodex</i> partially appreciated in an eyelash follicle at presentation (arrows) (a,b). <i>Demodex folliculorum</i> is imaged in its entirety (c) (from Morkin & Hamrah 2016).....	38
Figure 14: <i>Demodex</i> glow in the dark (from Aytekin 2016) .....	39
Figure 15: Efficacy of lid hygiene with sterile wipes impregnated with a micellar solution (from Rykov 2017).....	47
Figure 16: Lid scrubbing with BlephEX®.....	48
Figure 17: Tea tree.....	50
Figure 18: <i>Demodex</i> count in patients receiving weekly TTO lid scrub plus daily lid scrub with TTO shampoo (from Gao 2005).....	51
Figure 19: Change in <i>Demodex</i> count (A) and OSDI score (B) after eyelid scrub in TTO group and control group (from Koo 2012).....	52
Figure 20: Terpinen-4-ol.....	53
Figure 21: Tea tree oil.....	53
Figure 22: Efficacy of the cleansing wipes on global ocular discomfort .....	54
Figure 23: Efficacy of the cleansing wipes on eyelid margin hyperaemia.....	55
Figure 24: Efficacy of the cleansing wipes on the number of cylindrical dandruff .....	56
Table 1: <i>Demodex</i> Taxonomic classification .....	15
Table 2: <i>Demodex</i> prevalence according to clinical studi .....	21
Table 3: <i>Demodex</i> in blepharitis .....	29
Table 4: Uludag ocular demodicosis clinical scoring.....	40
Table 5: <i>Demodex</i> tested treatments: synthesis.....	57
Table 6: Management of <i>Demodex</i> blepharitis in 6 steps .....	61





# 1

## INTRODUCTION

Whilst *Demodex* were first described in detailed illustrations in 1847 (G. Simon, German dermatologist), interest in the human parasite *Demodex* has experienced a recent revival amongst health professionals across the world (Figure 1). The role of *Demodex* in human eyelid inflammation has long been debated, and in fact, the relationship between this parasite and its human host in eye health and disease remains equivocal. According to an increasing number of publications, an association between *Demodex* and certain pathologies such as rosacea or blepharitis seems likely. But as *Demodex* is a natural saprophyte of the skin, what is normal and how to define infestation? Is there a causal relationship between the mite and the disease, or is the disease merely creating a favorable environment for the mite to thrive? Is it clinically relevant to treat *Demodex* and what do we mean by 'treating': eradicate or restore the basic state? Is it necessary to use specific *Demodex*-killing treatments or is lid hygiene adequate? How should we evaluate the efficacy of treatments: on symptoms or on the mites count? Who, when, how long and how often is it relevant to treat and which treatments are safe and effective?

Some questions have been answered on *Demodex*, but many remain and new ones arise. This review examines the current literature to date surrounding this topic and its importance in anterior eye disease.

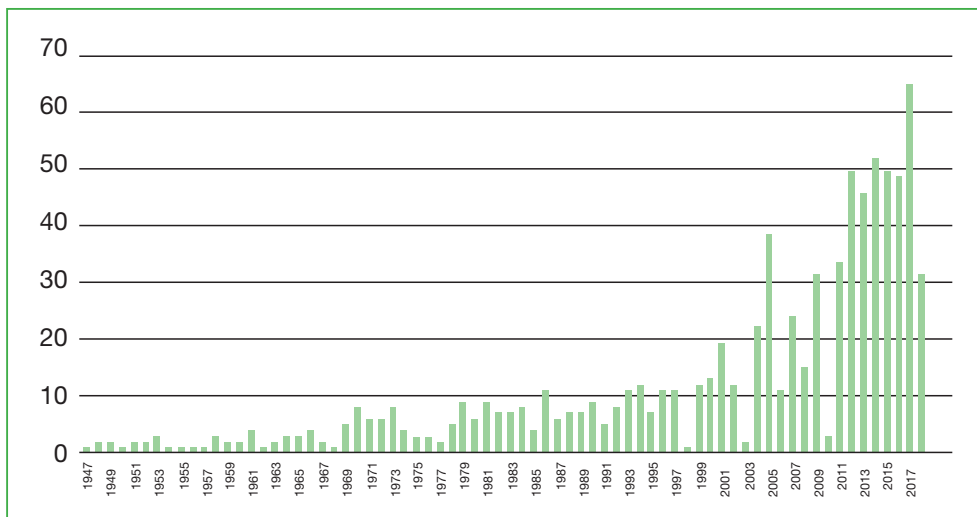


Figure 1: Pubmed publications count from 1947 to April 2018

# 1.1 DEMODEX BACKGROUND AND EPIDEMIOLOGY ASPECTS

*Demodex* are tiny mites (from the Greek words: Demos - fat; dex – worm) that live in or near the lash follicles and sebaceous glands of mammals. In classification terms they are Arthropods, members of the Arachnida (spider) class and Acari subclass (Table 1).

<b>Kingdom</b>	Animalia (Animals)
<b>Phylum</b>	Arthropoda (Arthropods)
<b>Class</b>	Arachnida (Arachnids)
<b>Subclass</b>	Acari (Mites and Ticks)
<b>Superorder</b>	Acariformes
<b>Order</b>	Trombidiformes
<b>Superfamily</b>	Cheyletoidea
<b>Family</b>	Demodecidae (Follicle mites)
<b>Genus <i>Demodex</i></b>	(Follicle mites)

Table 1: *Demodex* Taxonomic classification

There are over 65 species of *Demodex* mite, many of which are found to be specific to mammals including cats, dogs, pigs, cattle, and some rodents. Indeed, the pathogenic role of these mites in animals is better understood than their role in humans: the most studied mite is *Demodex canis* in dogs which causes demodectic mange (also known as follicular mange or red mange) (Lacey 2011; Sharma & Gupta 2014).

*Demodex* in humans is the only permanent human ectoparasite, and was first described and classified into two distinct species *Demodex folliculorum* and *Demodex brevis* more than 170 years ago (Chen & Plewig 2015) (Figure 2).

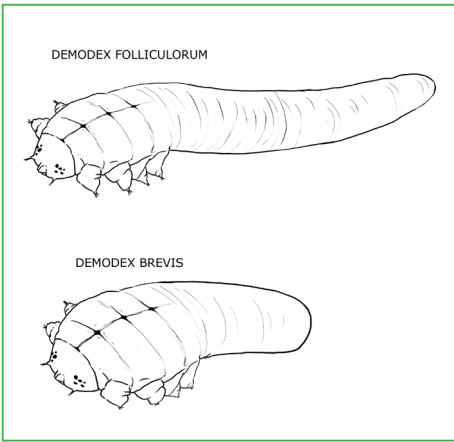


Figure 2: *Demodex folliculorum* and *Demodex brevis*

*Demodex folliculorum* and *Demodex brevis* are the only species of *Demodex* claimed to be etiologic pathogens of human demodicosis (*Demodex* infestation). They are thought to be specific to humans, and direct contact is necessary for transmission between people; typically transferred between hosts through contact of hair, eyebrows, and sebaceous glands on the nose. *Demodex folliculorum* is more commonly localized to the face, while *Demodex brevis* is more commonly found on the neck and chest (Forton 1986). In the eyelids, *Demodex folliculorum* are found in eyelash follicles, and *Demodex brevis* burrows deep into sebaceous glands and meibomian glands. *Demodex folliculorum* tends to live in clusters, whereas *Demodex brevis* tends to live individually in the meibomian glands (Figure 3).

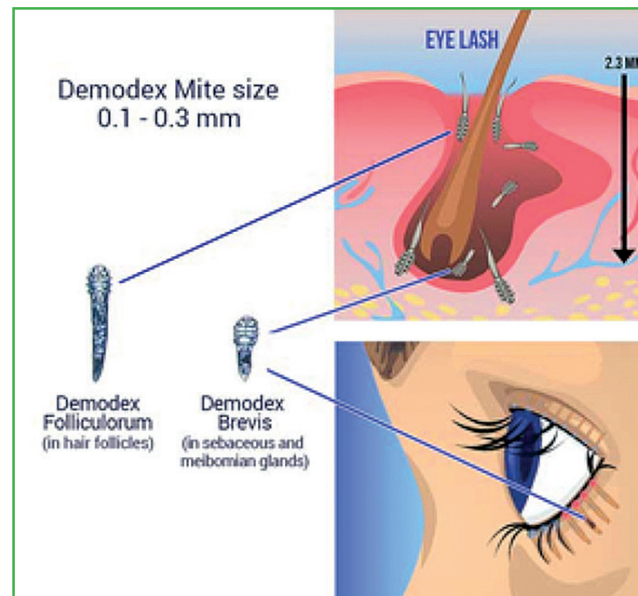


Figure 3: *Demodex* positioning in eyelash follicles (reproduced by permission of David Crystal)

The adult mite is white or yellow in colour, fairly translucent, with an elongated oval shape that tapers at the rear. Their bodies are covered by an exoskeleton with four pairs of articulated legs. There is a mouth, male and female genital organs (females tend to be slightly rounder and shorter than males), and a digestive pouch but no anus (Rather & Hassan 2014) (Figure 4). *Demodex* mites feed on sebum and skin cells that accumulate around the follicle and lid margin, and possibly keratin for their exoskeleton (Litwin 2017; Nicholls 2017). It is also suggested that *Demodex* species feed on the skin commensal bacteria around the lashes (Lacey 2011).

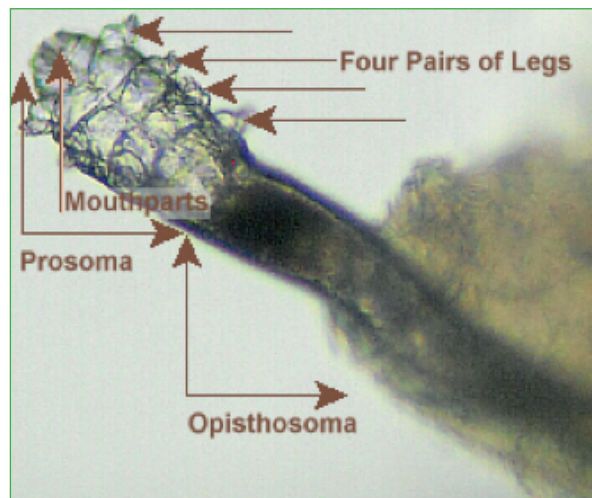


Figure 4: Demodex anatomy

*Demodex folliculorum* is 0.3-0.4 mm long; typically at least three or four mites are found as a cluster in the hair follicle, whereas *Demodex brevis* is usually solitary and smaller and stubbier (0.2-0.3 mm), and is found in the sebaceous and meibomian glands (Nutting & Green 1976; Lacey 2009; Rufli & Mumcuoglu 1981; Wesolowska 2014; Litwin 2017), and tends to be seen less frequently (English 1971; Wesolowska 2014). At this size, they are invisible to the naked eye and move around slowly (8-16mm/hr), generally at night so as to avoid bright light that will cause them to recede into follicles (Rather & Hassan 2014). *Demodex* isolated from eyelashes tend to be longer than those from the skin (Wesolowska 2014) (Figure 5).

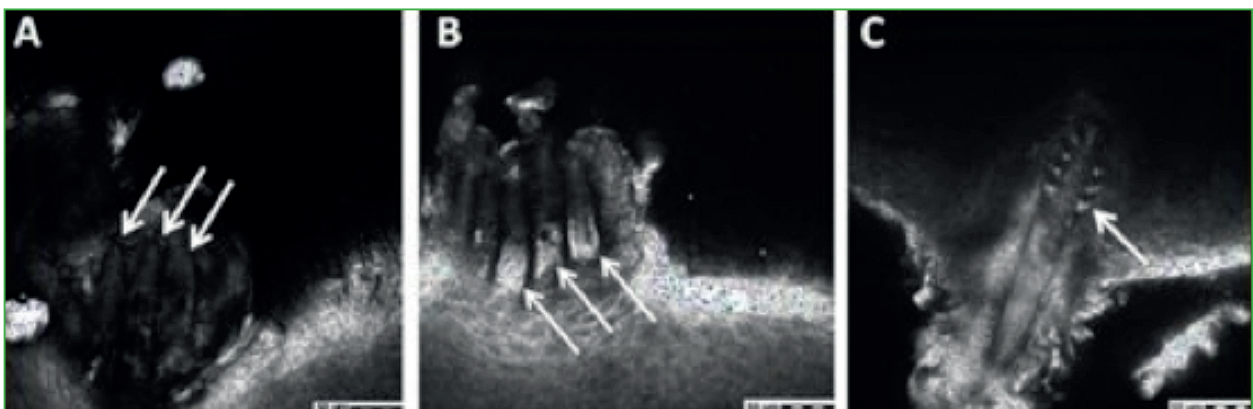


Figure 5: Eyelid in vivo confocal microscopy. Adult forms of Demodex (arrows) (from Morkin & Hamrah 2016)

## 1.2 THE LIFE CYCLE OF *DEMODEX* MITES

The life cycle is between 14 and 18 days from egg through larval and nymph stages, followed by 5 days as an adult mite (Figure 6). Adult females may live an extra 5 days after laying their eggs (Rufli & Mumcuoglu 1981; Wesolowska 2014).

The adult mites mate near follicle openings, then the female lays 10-12 eggs in the follicles or sebaceous glands; larvae appear after 3-4 days, and the resultant nymphs emerge and then re-enter a hair follicle into adulthood (Rufli & Mumcuoglu 1981; Lacey 2009). When mites die they simply decompose within the follicles or glands, and away from their host, their survival is severely limited, particularly in dry conditions (Rusiecka-Ziółkowska 2014).

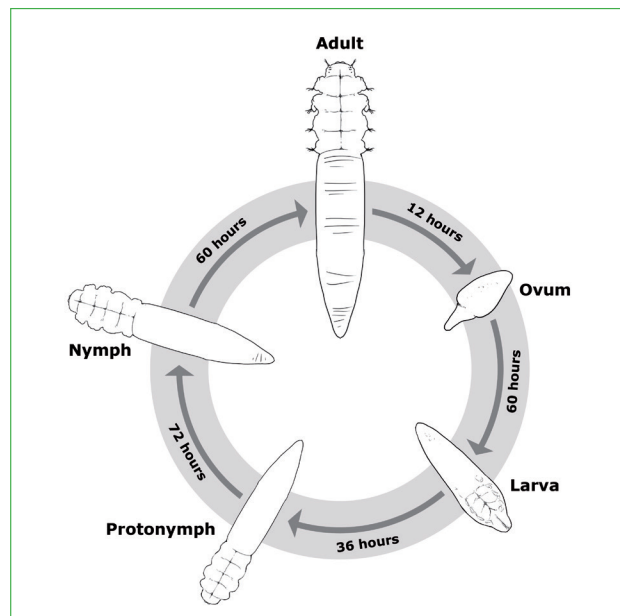


Figure 6: *Demodex folliculorum* life cycle

### KEY POINTS

- *Demodex* are tiny arthropods belonging to the Arachnids class and Acari sub-class.
- Two species, *Demodex folliculorum* and *Demodex brevis* are etiologic pathogens of human demodicosis (*Demodex* infestation).
- *Demodex folliculorum* is found in eyelash follicles, and *Demodex brevis* in the sebaceous and meibomian glands.
- *Demodex folliculorum* full life cycle lasts between 14 and 18 days.

## 1.3 PREVALENCE OF *DEMODEX* IN HUMANS

Every human being may host a colony of 1000 to 2000 *Demodex* mites (Litwin 2017). Both species are found in several populations around the world and different ethnic groups (Nutting & Green 1976; Andrews 1982; Wesolowska 2014; Vargas-Arzola 2012), and in regions where the climate is warmer (Madeira & Sogayar 1993). Most humans are infested by *Demodex folliculorum*, but *Demodex brevis* is often found in the same host. The prevalence of these two mite species is mostly different in eyelid hair follicles, where *Demodex brevis* is rarely recorded (Litwin 2017).

Various studies have shown that normal rates of colonisation vary between 20% and 100% (Norn 1971; Rufli & Mumcuoglu 1981; Elston 2010). A more recent study in Turkey examined superficial skin biopsies from 300 healthy volunteers, revealing a prevalence and density for *Demodex folliculorum* and *Demodex brevis* of 61.3% (mean 14.3/cm<sup>2</sup>) and 23.3% (mean 3.2/cm<sup>2</sup>), respectively (Tilki 2017).

Close contact is required for transmission; *Demodex* mites are acquired shortly after birth from adults (Lacey 2009). At this stage they are considered normal skin fauna, and there are few reports of significant colonisation in children and young adults with normal immune systems and nutrition (Basta-Juzbasic 2002; Kaya 2013), but some experts suspect it is more common in children than currently estimated (Schachter & Hom 2013).

Infestation increases with age, and consequently its presence in older adults is widespread; 84% in people older than 60 years and in 100% of people over 70 years of age (Norn 1971; Forton 1986; Aylesworth & Vance 1982; Rather & Hassan 2014; Hom 2013; Kasetsuwan 2017). It may be hypothesized that such a wide infestation in older people could be promoted by the high prevalence of Meibomian Gland Dysfunction (MGD) in elderly, as well as reduced immunity and possibly poorer hygiene habits in this population (Vargas-Arzola 2012).

Infestation of both *Demodex folliculorum* and *Demodex brevis* is more common in males than in females, possibly due to the greater number of sebaceous glands (Aylesworth & Vance 1982; Hu & Wang 2001; Tilki 2013).

## 1.4 PREVALENCE OF OCULAR *DEMODEX*

*Demodex* infestation from the face can migrate during darkness to the eyelids. The presence of *Demodex* in the eyelash follicles and lid margins was first described over 100 years ago (Rusiecka-Ziółkowska 2014), but consensus around its clinical significance remains poor amongst ophthalmologists as it can be observed in asymptomatic subjects as well as those with ocular disease or abnormalities.

Typical prevalence of *Demodex* in epilated eyelashes is similar to the general prevalence from skin biopsies, but varies between studies (Table 2).

In clinical populations the prevalence detected from eyelash sampling is reported to be between 54% (Wesolowska 2014) and 70% (Lee 2010). In a more general population, the picture is more varied: from 18% to 55% (Bhandari & Reddy 2014; Kemal 2005; Wesolowska 2014; Kabatas 2017), and is not always higher in symptomatic patients.

*Demodex folliculorum* is much more common (2.4 x) amongst sampled eyelashes than *Demodex brevis* (Wesolowska 2014; Litwin 2017; Tilki 2017) which is not surprising as *Demodex brevis* is burrowed deep within sebaceous glands and possibly in meibomian glands rather than in follicles.

The eyelid prevalence appears to increase with age (Wesolowska 2014; Lee 2010; Kemal 2005; Kasetsuwan 2017). *Demodex* numbers in eyelash samples from males and females are similar (Lee 2010).

The identification method may affect the claimed prevalence: with DNA extraction, a study found a prevalence of 78%, much higher than the one of 42% observed in optical microscopy (Kasetsuwan 2017).



Author year	n	Population	Method	Prevalence	Influence of age	Presence related to symptoms?	Presence related to sex?
Gao et al. 2005	55	3 groups A = diffuse CD B = sporadic CD C = clean lashes	Lash epilation	100% 100% 22%	No	?	?
Kemal et al. 2005	500	2 groups (Turkey): Seborrheic blepharitis (170) Controls (330)	Lash epilation	27.4% overall 28.8% 26.7%	Yes, but not significant	No	No
Lee et al. 2010	170	Routine clinical population	Lash epilation	70%	Yes	Yes	No
Vargas-Arzola et al. 2012	1010	General population Oaxaca, Mexico	Lash epilation	20%	Yes	No	Yes
Wesolowska et al. 2013	290	4 groups (Poland): In-patients; Drug addicts; Health professionals; Medical students	Lash epilation	41% 54.7% 23.5% 40% 33.7%	Yes	No	No
Bhandari et al. 2014	200	4 groups (India): Anterior Blepharitis (30) MGD (60) Mixed (60) Controls (50)	Lash epilation	68% overall 90% 60% 90% 18%	?	Yes	Yes (m)
Kabatas et al. 2017	118	2 groups (Turkey): Blepharitis (67) Control (51)	Lash epilation	67.2% 54.9%	?	Yes	No
Kasetsuwan et al. 2017	100	Random selection from Tertiary Care Center, Bangkok, Thailand	Lash epilation DNA extraction	42% 79%	Yes	No	?

Table 2: Demodex prevalence according to clinical studies

MGD = Meibomian Gland Dysfunction  
CD = Cylindrical Dandruff

### KEY POINTS

- *Demodex folliculorum* and *Demodex brevis* prevalence in humans has been found to be 61% and 23%, respectively.
- More specifically in the eye, in a general population, the prevalence varies from 18% to 55% and is not always higher in symptomatic patients.
- In populations with blepharitis symptoms, *Demodex* prevalence from eyelash sampling is reported to be between 54% and 70%.
- Infestation increases with age: 84% in people older than 60 years and in 100% of people over 70 years old.

## 1.5 DEMODEX IN THE PATHOGENESIS OF SKIN DISEASE

The pathogenic role of human *Demodex* mites in certain inflammatory skin diseases remains debated. They have been implicated in multiple skin disorders with white follicular scales, papules, and pustules such as pityriasis *folliculorum*, papulopustular and granulomatous rosacea, inflammatory papule, folliculitis, seborrheic dermatitis, perioral dermatitis and blepharitis (Zhao 2011; Litwin 2017).

The sampling method for facial *Demodex* is called 'Standardized Skin Surface Biopsy' (SSSB), a method in which 1 cm<sup>2</sup> of the superficial part of the horny layer of the skin and the follicular content are collected. To increase the sensitivity, the skin and the biopsy slide are cleaned with ether before the SSSB and a second, and therefore deeper, SSSB is performed at the same site immediately after the first (Forton & De Maertelaer 2017).

Rosacea is the condition with the strongest evidence implicating *Demodex* as a causal agent. As long ago as 1992, *Demodex folliculorum* was identified in most rosacea patients, but only in a few control subjects (Sibenge 1992; Bonnar 1993). A meta-analysis subsequently found an Odds Ratio (OR) of 7.57 for association between rosacea and *Demodex* infestation (Zhao 2010). Moreover, in a case-control study performed the following year by the same authors, *Demodex* infestation was demonstrated to be statistically associated with rosacea (OR=8.1), steroid-induced dermatitis (OR=2.7), seborrheic dermatitis (OR=2.2), and primary irritation dermatitis (OR=2.1) (Zhao 2011). More recently, a 58.5% prevalence of *Demodex* was reported by a case-control study in patients with rosacea compared to 19.5% in patients free from rosacea (Gonzalez-Hinojosa 2017).

In seborrheic dermatitis, a case-control study found the number of *Demodex* mites to be significantly higher in both lesional and non-lesional areas compared with control patients (Karincaoglu 2009). But prevalence the other hand, another study on 180 patients with mild dermatologic complaints (mild itching or scaling or erythema) failed to establish any relation between *Demodex* and seborrheic dermatitis or atopic dermatitis (Tehrani 2014).

Recently, human demodicosis has been suggested to be a primary disease in its own right, with different clinical presentations including:

- ▶ pityriasis folliculorum;
- ▶ papulopustular/nodulocystic or conglobate demodicosis with pronounced inflammation affecting most commonly the perioral and periorbital areas of the face;

- ▶ ocular demodicosis, inducing chronic blepharitis, chalazia or, less commonly, keratoconjunctivitis;
- ▶ and auricular demodicosis causing external otitis or myringitis (Chen 2014).

A secondary form would be mainly associated with systemic or local immunosuppression (Chen 2014). According to Chen (2014), human demodicosis can mimic many other inflammatory skin disorders, such as folliculitis, rosacea and perioral dermatitis, leading to unspecific and confusing descriptions in the literature.

Hence, much controversy persists around *Demodex* and its possible association with skin disorders. Furthermore, in any case, it is not clear whether potentially associated skin disorders merely provide a suitable environment for multiplication of mites, or the mites play a role in the pathological changes (Chen & Plewig 2015).

#### KEY POINTS

- In dermatology, *Demodex* mites are strongly associated with rosacea.
- Demodicosis can mimic numerous other inflammatory dermatoses.
- It is not clear whether *Demodex* has a causal role in those dermatoses or if those dermatoses provide only a suitable environment for the mites to thrive.

## 1.6 DEMODEX IN THE PATHOGENESIS OF EYE DISEASE

Baudouin (2016), developed a new Dry Eye Disease (DED) schematic that encompassed MGD and illustrated how the related physiopathological mechanisms underlying DED and MGD combine to form one chronic form of MGD-associated DED. This has been described as a double vicious circle illustration (Figure 7): the mechanisms of DED and MGD interact, resulting in a double vicious circle in which proliferation of *Demodex* mites can exacerbate the pathophysiological effects.

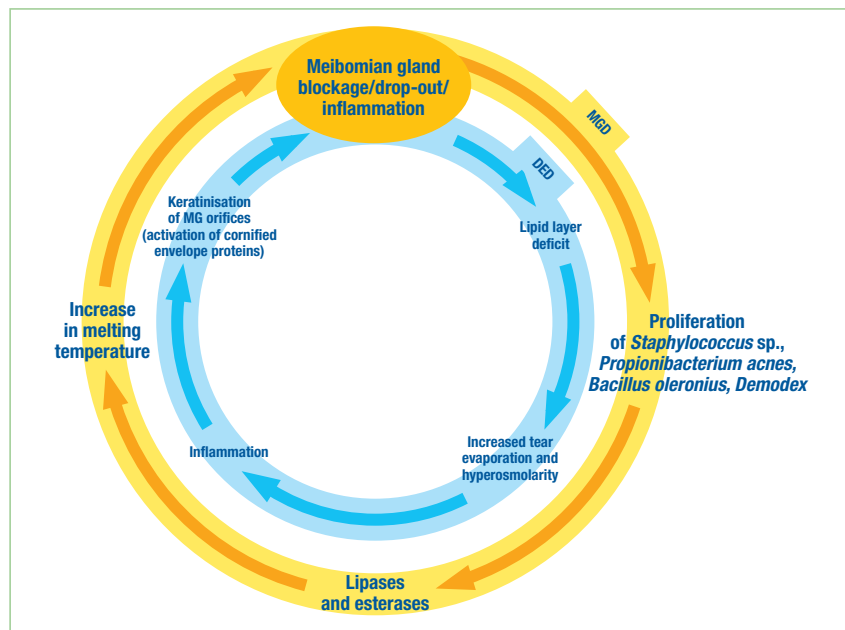


Figure 7: Importance of meibomian gland dysfunction in the vicious circle of the pathology of dry eye disease (adapted from Baudouin 2016).

Where *Demodex* are present in hair follicles but the human host is unaffected, they may be considered truly commensal, but where *Demodex* mites are associated with skin or eye problems, they are described as true parasites. To date there is no evidence to suggest that we actually benefit from the mites, but some experts have speculated that *Demodex* mites may serve a purpose by scavenging excess of sebum or bacteria (Grice & Segre 2011; Czepita 2007).

The exact pathogenic role for *Demodex* in ocular disease continues to be debated because mites can also be found on the skin and lashes of asymptomatic individuals. Elevated *Demodex* loads have been reported in rosacea, seborrheic dermatitis, perioral dermatitis and blepharitis (Zhao 2011; Litwin 2017), so many clinicians adopt a logical approach whereby they consider that over-colonisation is probably causal for disease and therefore requires treatment. However, in truth the maximum number of mites that can be tolerated by an individual is yet to be determined.

The possible mechanisms for blepharitis due to *Demodex* species are described below. It is unlikely that these occur in isolation, moreover a combination of:

### Physical damage

The occupation/irritation of follicles and glands leads to reactive hyperkeratinization, distended follicles and epithelial hyperplasia (Kabatas 2017). The mites also excrete lipases to digest sebum which can irritate the eye lid margins (Bhandari & Reddy 2014). Indeed,

this excretion may increase the viscosity and the melting temperature of the meibum, reducing its secretion onto the surface of the tear film. The meibomian glands underpin the double vicious circle of both DED and MGD, described by Baudouin (2016), and can act as an entry point. By infesting the follicles, the *Demodex* mites further reinforce the vicious circle of MGD leading to tear film instability, hyperosmolarity and inflammation, that are cause and consequence of DED (Baudouin 2016). Physical obstruction of meibomian glands will also cause obstructive MGD, in turn reducing the quality and stability of the superficial layer of the tear film (Kabatas 2017).

### ***Demodex* mites may simply give rise to an inflammatory cascade rather than causing direct damage to tissue**

This may be in reaction to the exoskeleton material (chitin), and its metabolic products (Wesolowska 2014). Infestation of *Demodex* mites is associated with changes of tear cytokine levels, Interleukin-17 (IL-17) especially, which can cause inflammation of the lid margin and ocular surface (Kim 2011).


The host response has been shown to be chiefly CD4 helper or Inducer T cells and also increased macrophages and Langerhans cells indicating an innate host response (Liu 2010; Nicholls 2017). In individuals with compromised immunity, *Demodex* infestation tends to be higher (Kaya 2013; Kulac 2008).

### ***Demodex* species can also act as a vector for antigens**

*Demodex* species present their own microflora such as *Streptococcus* and *Staphylococcus*, which may then act as co-pathogens in disease. Indeed, the parasites are able to act as a carrier of the bacteria *Bacillus oleronius* (serum reactivity can be demonstrated), which acts as co-pathogen in the development of severe forms of blepharitis (Szkardkiewicz 2012). A similar role for these bacteria has also been shown in rosacea (Jarmuda 2014), and in blepharitis associated with high *Demodex* count and facial rosacea (Li 2010). Two in vitro studies (O'Reilly 2011 & 2012; McMahon 2014) have also demonstrated increased expression for inflammatory responses in corneal epithelial cells, reduced cell proliferation and aberrant wound healing responses, when exposed to *Bacillus* proteins associated with *Demodex*, suggesting a potential role in ocular surface degradation.

#### **KEY POINTS**

- *Demodex* is considered to play a role in the pathogenesis of eye diseases by causing chronic blepharitis.



2

## ***DEMODEX* BLEPHARITIS**

According to Zhao and colleagues (2012), and cited in TFOS DEWS II report, '*Demodex* infestation is a causative factor in many cases of intractable blepharitis and is often associated with dry eye symptoms' (TFOS DEWS II 2017; Zhao 2012).

Some researchers have clearly demonstrated a high prevalence of *Demodex* in eyelash follicles in blepharitis – so called '*Demodex* Blepharitis' – but some studies have observed similar levels of *Demodex* amongst healthy eyelids as amongst those with blepharitis signs and symptoms (Table 3). It should be remembered that such lack of consensus would be due, at least in part, to differing methodology for sampling and a paucity of studies in this area (see section 3 on detection). A meta-analysis by Zhao (2012) included eleven articles covering four different countries and reporting 4741 participants (2098 blepharitis and 2643 controls); they concluded a statistically significant association between *Demodex* infestation and blepharitis. They also stated that 'when conventional treatments for blepharitis fail, examination of *Demodex* mites and acaricidal therapy should be considered'.

Several studies conducted posteriorly to the 2012 meta-analysis observed a higher prevalence of *Demodex* in blepharitis patients than in healthy controls (Bhandari & Reddy 2014; Kabatas 2017).

Furthermore, a recent study focusing specifically on refractory blepharitis found a high prevalence of *Demodex* (76.9%) in those patients. The Uludag Ocular Demodicosis clinical Scoring (UODS) symptom score was significantly higher in *Demodex* positive patients than in *Demodex* negative patients (Alver 2017). This clinical scoring is defined in section 3.5.



Author year	n	Population	Method	Prevalence	Influence of age	Presence related to symptoms?	Presence related to sex?
Shi et al. 1984*	70	2 groups: Blepharitis (27) Healthy eyes (43)		48.15% 11.63%			
Guan et al. 1989*	231	2 groups: Blepharitis (15) Controls (216)		60% 12.04%			
Li et al. 1996*	228	2 groups: Blepharitis (63) Controls (165)		23.81% 9.7%			
Demmler et al. 1997	247	2 groups: Blepharitis (139) Controls (108)	Lash epilation	52% 28.7%	?	?	?
Tu'er et al. 1997*	197	2 groups: Blepharitis (20) Controls (177)		60% 47.46%			
Zu et al. 2002*	826	2 groups: Blepharitis (426) Controls (400)					
Tian et al. 2004*	1300	3 groups: Blepharitis (507) Other ocular pathologies (498) Normal eyes (295)		50.69% 11.62% 7%			
Kemal et al. 2005	500	2 groups (Turkey): Seborrheic blepharitis (170) Controls (330)	Lash epilation	27.4% overall 28.8% 26.7%	Yes, but not significant	No	No
Turk et al. 2007	96	2 groups: Blepharitis (48) Healthy controls (48)	Lash epilation	38.81% 4.16%	?	Yes	?
Anane et al. 2007	165	2 groups: Blepharitis (69) Controls (96)		57.97% 15.63%	No	?	No
Lee et al. 2010	170	Routine clinical population (170)	Lash epilation	70%	Yes	Yes	No
Mu et al. 2010*	156	2 groups: Blepharitis (91) Controls (65)		90% 32.3%			
Wesolowska et al. 2013	290	4 groups (Poland): In-patients; Drug addicts; Health professionals; Medical students (290)	Lash epilation	41% 54.7% 23.5% 40% 33.7%	Yes	No	No
Bhandari et al. 2014	200	4 groups (India): Anterior Blepharitis (30) MGD (60) Mixed (60) Controls (50)	Lash epilation	68% overall 90% 60% 90% 18%	?	Yes	Yes (m)
Kabatas et al. 2017	118	2 groups (Turkey): Blepharitis (67) Controls (51)	Lash epilation	67.2% 54.9%	?	Yes	No
Alver et al. 2017	39	Chronic refractory Blepharitis (39)	Lash epilation	76.9%		Yes	

\* Original articles in Chinese without available abstracts / Data extracted from Zhao 2012 meta-analysis providing no information other than prevalence

Table 3: Demodex in blepharitis

## 2.1 RISK FACTORS AND COMORBIDITIES IN *DEMODEX* BLEPHARITIS

### AGE

As in *Demodex* elsewhere on the face, incidence and prevalence increase with age (Lee 2010; Wesolowska 2013; Kabatas 2017).

### SEX

Some studies suggest *Demodex* blepharitis is more common in men (Aylesworth & Vance 1982; Hu & Wang 2001; Tilki 2013).

### CONTACT LENS WEAR

Significantly more *Demodex* are observed in contact lens wearers compared to no-lens wearers, but not necessarily having clinical impact (Jalbert & Rejab 2015). It has been suggested that *Demodex* may be a factor in contact lens comfort and ultimately drop out (Tarkowski 2015a). In this study, 94% of intolerant contact lens wearers had *Demodex*, compared to only 6% in tolerant wearers.

### KERATITIS

Several cases of refractory keratitis have been found to be associated with a *Demodex* infestation, with an unusual high proportion of *Demodex brevis*. These cases had been previously diagnosed as herpetic keratitis but failed to respond to antiviral therapies. They were successfully treated by the mite eradication (Luo 2017).

### CHALAZIA

There is a high prevalence of *Demodex*, especially *Demodex brevis*, in both adults and children with chalazia (Liang 2014; Yam 2014; Schear 2016; Tarkowski 2015b; Luo 2017).

### ROSACEA

A strong correlation between severity of rosacea and *Demodex* blepharitis has been demonstrated, which suggests that the factors that influence rosacea such as sunlight exposure, alcohol intake, smoking, stress, spicy food, hot beverages, and exposure to abrupt temperature changes, will also exacerbate *Demodex* blepharitis (Liu 2010).

## POOR HYGIENE

It has been suggested that poor and/or crowded living conditions make *Demodex* blepharitis more likely (Vargas-Arzola 2012).

## IMMUNODEFICIENCY

In patients whose local or systemic immunity is compromised by medication, malnutrition or illness, infestation of *Demodex* mites can develop (Kaya 2013; Kulac 2008).

## 2.2 CLINICAL PRESENTATION OF *DEMODEX* BLEPHARITIS

The use of the term '*Demodex* blepharitis' is reserved for where the infestation with *Demodex folliculorum* and/or *Demodex brevis* is thought to be implicated in the pathogenesis and subsequent management.

### 2.2.1 SYMPTOMS

- ▶ Lid margin itching
- ▶ Foreign body sensation
- ▶ Burning
- ▶ Tearing
- ▶ Where *Demodex* are present in blepharitis, itching is the most significant sign, followed by foreign body sensation (Kabatas 2017).

### 2.2.2 CLINICAL SIGNS

There are several signs associated with a *Demodex* infestation (Liu 2010) (Figure 8):

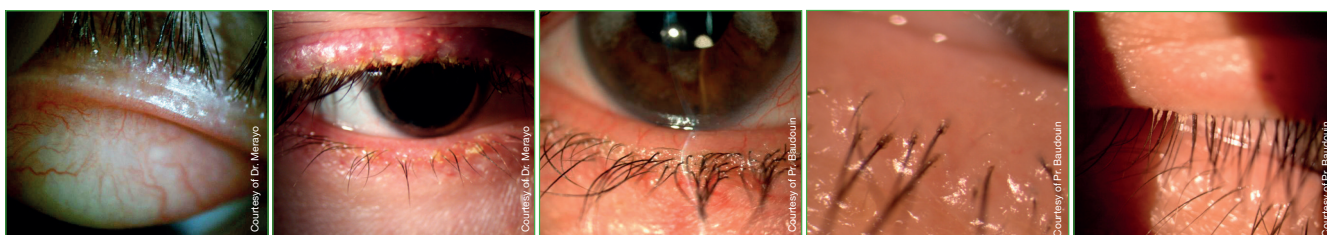


Figure 8: Ocular signs caused by *Demodex* infestation

- ▶ Crusting and redness of the lid margin
- ▶ Misdirected lashes
- ▶ Follicular hypertrophy
- ▶ Debris around lid margin – anterior blepharitis (non-specific sign)
- ▶ Cylindrical dandruff or collarettes (Figure 9)

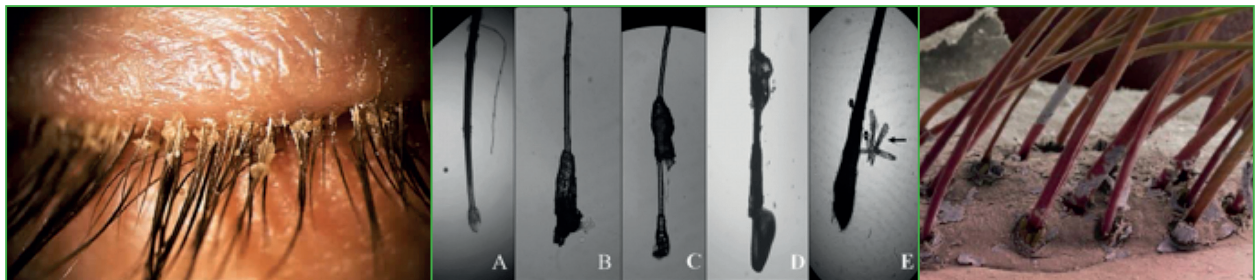


Figure 9: Collarettes (cylindrical dandruff)

- ▶ Recurrent chalazia
- ▶ MGD
- ▶ Tails pouting from follicles when collarettes are removed

The presence of cylindrical dandruff at the base of the lash is almost pathognomonic of the presence of *Demodex* in an untreated patient (Coston 1967; Norn 1970; Gao 2005; Cheng 2015; Kabatas 2017). However, the relationships between symptoms, other signs and the number of collarettes are weak, meaning that detecting collarettes is more useful as a diagnostic technique than as an outcome measure for successful management.

Whilst there is no published consensus on what the collarettes are made of, it is suggested that they are a direct result of *Demodex*'s consumption of epithelial cells in the follicles, their claws causing micro-abrasions with resultant hyperplasia and reactive hyperkeratosis (Kabatas 2017). It is suggested they contain lipids, decomposed mites and keratin (Gao 2005).

*Demodex* mites do not have an anus to excrete waste from; faeces are only expelled when the mite dies and decomposes. Recently, other authors suggested that the collarettes

are made of the bacterial biofilm which is deposited on the lid margin and inside the hair follicle. As the lash grows, small pieces of biofilm adherent to the lash will be pulled free of the lid margin and become 'cylindrical dandruff'. This would explain why these collarettes appear at different levels along the eyelashes, since the lashes are all growing at different times and stages (Rynerson & Perry 2016).

### 2.2.3 COMPLICATIONS IN *DEMODEX* BLEPHARITIS


- ▶ Blepharoconjunctivitis
- ▶ Blepharokeratoconjunctivitis (BKC)
- ▶ Madarosis
- ▶ Trichiasis

Chronic infestation of the lash follicles will lead to misdirection of lashes, trichiasis and ultimately madarosis (Sachdeva & Prasher 2008). Various forms of conjunctival and corneal inflammation, as commonly observed in ocular rosacea, can be found in patients with *Demodex* infestation of the eyelids (Kheirkhah 2007). *Demodex brevis*, which at the eye level is found mainly in the meibomian glands, may cause keratitis, superficial corneal vascularisation, marginal infiltration, and BKC.

*Demodex* blepharitis should certainly be considered as a potential cause of refractory blepharoconjunctivitis in children (Liang 2010).

#### KEY POINTS

- *Demodex* presence is strongly associated with blepharitis, especially when chronic and resistant to first line treatments.
- Aging, contact lenses intolerance, chalazia, rosacea, ocular surface disorders, immunodeficiency, poor hygiene may all be associated to *Demodex* infestation.
- Symptoms of lid itching and presence of cylindrical dandruff are indicative of excessive numbers of *Demodex* in human eyelids.
- Untreated, *Demodex* blepharitis may lead to severe ocular complications.



# 3

---

## **DIAGNOSING *DEMODEX* INFESTATION IN OPHTHALMOLOGY**

Historically, when magnification in ophthalmic practice was limited to 16-20x technology, clinicians could only observe collarettes around the base of the eyelashes but not the *Demodex* mites themselves.

Removing the crusting and cylindrical dandruff for 'a better look' at the lid margin would not be routine practice in many busy clinics, meaning that any *Demodex* tails protruding from the follicle were hidden from view. With this in mind, *Demodex* infestation in ophthalmology is likely to have been under-diagnosed and under-managed in the past.

### 3.1 LASH SAMPLING/EPILATION AND MICROSCOPIC EVALUATION

This method involves removing lashes from each eyelid, storing and transferring to a microscope slide so that they can be observed ex-vivo under a light microscope.

Differences between clinicians and researchers center around the number of lashes sampled, the fixing process and the definition of '*Demodex* positive' for your diagnosis. Some clinicians remove 2 or 4 lashes per lid – a total of at least 8 lashes each time you wish to monitor outcomes and progress, and of course not all lash follicles may have *Demodex* so this can lead to false results. It is recommended that sampling is not random but restricted to lashes where collarettes are obvious (Hom 2013; Bhandari & Reddy 2014).

The challenge once the lash is removed is getting the mite to stay with the lash: as they are naturally light averse they will attempt to retreat, and prone to dessication. It seems using sticky tape to adhere lash (and mite) to slide is favored, as opposed to oil or even saline solution (Kabatas 2017).

The epilated eyelashes are then mounted with a coverslip after addition of a drop of oil, such as peanut or olive oil. The number of mites per number of lashes is counted under a light microscope. One or two per sixteen lashes is a 'normal' mite population sampling. Over six, and especially if four or five are counted on one lash, the lid is regarded as over-populated (Coston 1967).

Mounting the lashes on a carrier slide with a concavity and add a drop of saline before setting the coverslip may prevent *Demodex* from floating away and result in a more accurate count (Bhandari & Reddy 2014).



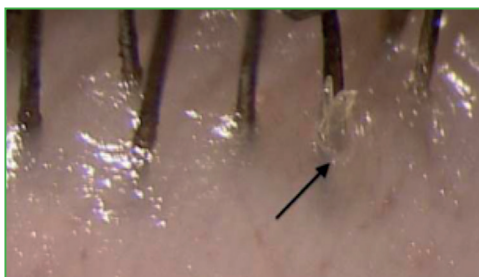
The addition of fluorescein solution after mounting has been demonstrated to improve the detection and count of mites (Kheirkhah 2007). Another method involves wet films stained with 1% aqueous methylene blue. The mite does not take up the stain but is clearly visible against the blue background (Canti 2010) (Figure 10).

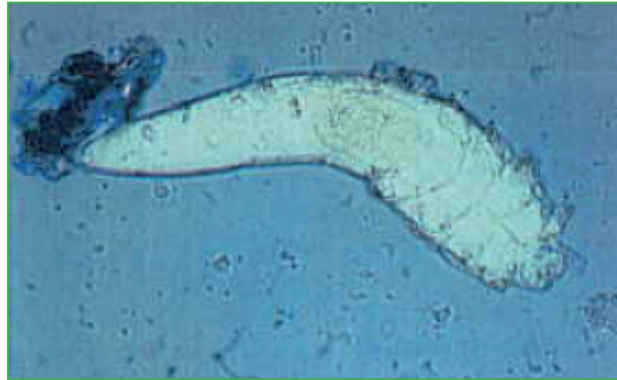

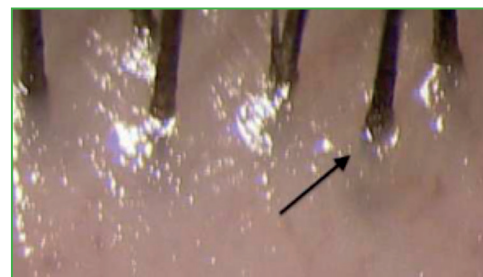
Figure 10: Demodex under optical microscopy with methylene blue (from Canti 2010)

### 3.2 LASH ROTATION/TRACTION AND LIGHT MICROSCOPY

Once the cylindrical dandruff is removed, it is often possible to see 3-4 tails just protruding from a single follicle. By pinching the affected lash with fine tweezers or forceps, and rotating it while observing under high magnification at the slit lamp, the tails will emerge more, such that you can extract a mite for microscopic examination (Figure 11).



Eyelash after rotation. Demodex organisms along the trunk of the lash, uprooted from within the eyelash follicle.



Eyelash with no Demodex organisms evident pre-lash rotation.

Figure 11: Lash rotation (from Mastrota 2013)

There is also another way to manipulate the lashes without using epilation: the Lateral Eyelash Traction (LET) (Figure 12). The LET is a validated technique where the lash is gently pulled to one side with fine forceps after cylindrical dandruff removal, using 25-40x magnification at the slit lamp. The LET technique appears to yield the highest numbers of mites per eyelash among a panel of other techniques (including lash rotation and lash epilation) (Muntz 2019).

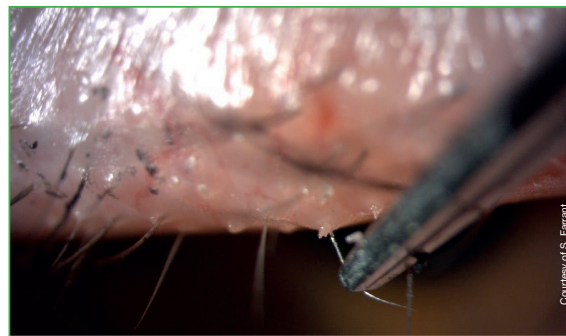


Figure 12: Lateral Eyelash Traction

Both techniques require no lashes to be pulled and sacrificed which is preferable for clinician and patient alike (Mastrota 2013; Muntz 2019).

### 3.3 *IN VIVO* CONFOCAL MICROSCOPY (IVCM)

IVCM shows promise as a useful technique for detection of *Demodex* in eyelids. When compared to traditional epilation, *Demodex* infestation was better characterised by IVCM in symptomatic patients when associated to MGD (Randon 2014). Moreover, the same study demonstrated that the sensitivity of IVCM was better for detecting low grades of infestation compared to traditional epilation. IVCM is thus an efficient and reliable tool for the diagnosis of eyelid mite infestation and may also provide an evaluation of meibomian glands (Figure 13).

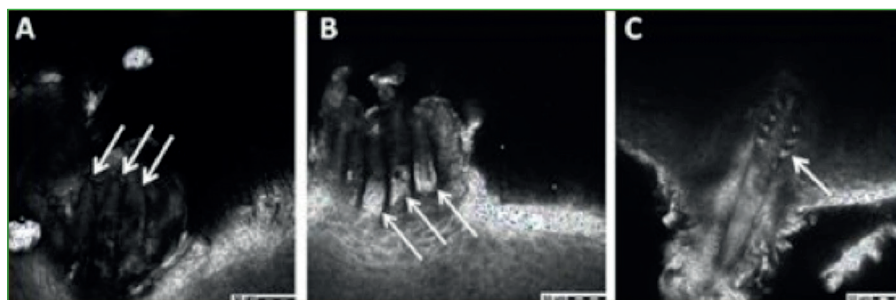


Figure 12: Eyelid in vivo confocal microscopy. Adult forms of *Demodex* partially appreciated in an eyelash follicle at presentation (arrows) (a,b). *Demodex folliculorum* is imaged in its entirety (c) (from Morkin & Hamrah 2016)

By utilizing IVCM in patients with rosacea, Liang (2017) first highlighted a positive correlation between the *Demodex* quantification in the eyelid and the cheek. Even in patients with relatively normal aspect of cornea, the meibomian glands presented *Demodex* in the follicle combined with round hyperkeratinised hyperreflective structures (Liang 2017).

In rosacea, Reflectance Confocal Microscopy (RCM) shows promise as an objective measure for clinical trials RCM, where a 'reduction in the density of *Demodex* mites in facial skin of patients with rosacea under therapy, correlating to clinical improvement, can be quantified and monitored non-invasively' (Sattler 2015). However, in eyelids, the reflection from the substantia propria makes it more challenging as a technique, leaving it generally limited to research or academic settings at the time of writing.

### 3.4 SPONTANEOUS FLUORESCENCE

Aytekin et al. discovered by accident, forgetting to turn on the microscope light, that *Demodex* is visible by fluorescence in the dark field. As the *Demodex* is covered by a thin chitinous exoskeleton with a mostly semi-transparent body, the authors assumed that the fluorescence came from the reflection of outer light sources by the chitinous exoskeleton, while the direct microscope light was off. For this examination, only immersion oil is used, without methylene blue or fluorescein (Aytekin 2016) (Figure 14).

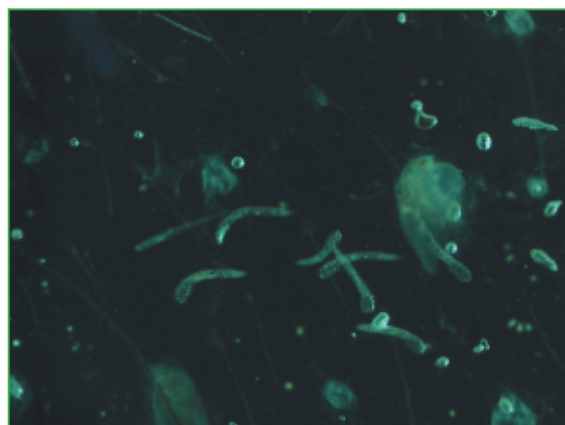


Figure 14: *Demodex* glow in the dark (from Aytekin 2016)

### 3.5 CLINICAL SCORING

A clinical scoring system has recently been proposed, referred as UODS (Alver 2017). The score integrates the most common complaints and clinical signs potentially linked to *Demodex* (Table 4). In their study, Alver (2017) found a high specificity, with 94% of patients with UODS of 4 or above and 85% with UODS of 3 or above having actually *Demodex*. However, the sensitivity is not very accurate, as only 54% of the *Demodex*-positive patients had scores of 4 or higher.

	Yes	No	Total
<b>Symptom</b>			
At least one of the symptoms that mentioned below is positive burning, stinging, itching, pain	<input type="checkbox"/>	<input type="checkbox"/>	-
<b>Finding</b>			
Anterior blepharitis	<input type="checkbox"/>	<input type="checkbox"/>	-
Posterior blepharitis	<input type="checkbox"/>	<input type="checkbox"/>	-
<b>Additional points</b>			
<u>Lashes</u>			
Cylindrical dandruff (if yes add 2 points)	<input type="checkbox"/>	<input type="checkbox"/>	-
<u>Ocular surface</u>			
Chronic user of an eye drop that contains preservative (if yes add 1 point)	<input type="checkbox"/>	<input type="checkbox"/>	-
Systemic or local any cause of dry eye diseases except blepharitis (if yes add 2 points)	<input type="checkbox"/>	<input type="checkbox"/>	-
<u>Cornea</u>			
Epithelial defect (if yes add 1 point)	<input type="checkbox"/>	<input type="checkbox"/>	-
Keratitis (if yes add 2 points)	<input type="checkbox"/>	<input type="checkbox"/>	-
Total score	-	-	-

Table 4: Uludag ocular demodicosis clinical scoring

### 3.6. DEMODEX DIAGNOSIS IN PRACTICE

As detailed above, several methods exist to identify *Demodex* infestation.

In clinical practice, it is neither time-efficient to search for *Demodex* in all patients with blepharitis or ocular surface changes, nor realistic to spend too much time confirming the diagnosis.

Thus, a step by step approach may optimize the search of *Demodex*.

**Suspect *Demodex* in patients with:**

- ▶ Chronic blepharitis or ocular surface inflammation
- ▶ Refractory to standard treatments (lid hygiene, artificial tears)
- ▶ Especially if risk factors and/or comorbidities are present (elderly, women, contact lenses intolerance, immunodeficiency, skin disease such as rosacea, etc.)

**Score clinical features associated with *Demodex* infestation (UODS) (Table 4).**

**Perform slit lamp examination** to detect the pathognomonic cylindrical dandruff around the base of eyelashes and count the dandruff number per lash. *Demodex* infestation should be suspected when counting more than 4 dandruff.

**Rotation should go next as a relatively non-invasive technique, before lash epilation.**

**In patients with very suggestive clinical presentation** and/or with dandruff, perform direct optic microscope examination:

- ▶ Choose 4 epilated lashes with collarettes per eye.
- ▶ Mount them with a drop of peanut or olive oil under coverslip, or with a drop of saline with 1% methylene blue or fluorescein.
- ▶ Set them under microscope, light on with addition of fluorescein or methylene blue or light off without fluorescein.
- ▶ Identify the mites and count them. Over 6, and especially if 4 or 5 are counted on one lash, the lid is regarded as overpopulated.



# 4

## **TREATING *DEMODEX* IN OPHTHALMOLOGY**

Historically, the treatment of ocular *Demodex* has included a wide variety of products, most of which had no high level evidence to support their use. These included topical 2% metronidazole gel, 1% mercury oxide ointment, and 4% pilocarpine gel.

More recently, alternative management has been found with the use of topical products containing Tea Tree Oil (TTO) or oral ivermectin (TFOS DEWS II 2017). For some of the treatments described here, clinical studies with *Demodex* count have been conducted in rosacea and not in blepharitis.

It should be noted that frequently treatments are judged to be effective when symptoms and mite numbers are reduced; this may not necessarily be that the treatment is actually 'killing' mites.

## 4.1 SYSTEMIC TREATMENTS

Like most parasites, *Demodex* may be treated systemically. Two antiparasitic systemic treatments have been tested on *Demodex*.

### Ivermectin

Ivermectin is an antiparasitic drug, used orally in the treatment of scab and some other parasitic diseases, and is indicated topically in inflammatory rosacea. Ivermectin causes death of parasites, primarily through binding selectively and with high affinity to glutamate-gated chloride channels, which occur in invertebrate nerve and muscle cells. Anti-inflammatory properties of cutaneous ivermectin have been observed in animal models of skin inflammation (SPC Ivermectin cream) through decreasing neutrophil phagocytosis and chemotaxis, inhibiting inflammatory cytokines such as IL-1b and Tumor Necrosis Factor-a (TNF-a), and upregulating the anti-inflammatory cytokine IL-10 (Cardwell 2016). The validated efficacy of topical ivermectin in rosacea may be related to both properties.

Two interventional non comparative case series in 12 and 19 patients with refractory posterior blepharitis and presence of *Demodex folliculorum* in lash samples, systemic ivermectin has been shown to reduce the number of *Demodex folliculorum*, and simultaneously, to improve the clinical symptoms and tear film stability (Holzchuh 2011; Filho 2011).



Several case reports have confirmed this efficacy in blepharitis refractory to usual treatments: resolution of a severe ocular and cutaneous rosacea with huge infestation by *Demodex folliculorum* unresponsive to oral doxycycline, oral isotretinoin, and topical tacrolimus with a single oral dose of ivermectin (Brown 2014) and resolution of a widespread erythema and scaling of the face associated to blepharitis and chalazia with *Demodex* infestation in an immunosuppressed patient, using a 6-week combined treatment of oral ivermectin and topical permethrin (Damian 2003).

Systemic ivermectin recommended dosage is 200 µg per kilogram of body weight in single dose (SPC Ivermectin 3 mg tablets); (Holzchuh 2011; Brown 2014; Salem 2013). In another study on *Demodex* related blepharitis, the dosage was 6 mg twice a day for 1 day, repeated after 14 days (Filho 2011).

### Metronidazole

Metronidazole is an antibiotic and antiparasitic drug, used orally in infections and infestations related to anaerobic bacteria, trichomonas, amoebae or giardia (SPC metronidazole p. os). It is also indicated topically in inflammatory forms of rosacea (SPC metronidazole topical).

Metronidazole reduces reactive oxygen species and decreases oxidative tissue injury by inhibiting neutrophil-generated cytokines. It also has anti-inflammatory and immunomodulatory effects that may contribute to its efficacy in rosacea therapy. Papulopustular rosacea patients treated with metronidazole had a decrease in the mean number of papules and pustules (Cardwell 2016).

In vitro, *Demodex* was found to survive in metronidazole concentrations of as much as 1 mg/ml (Persi 1981), which does not suggest a strong efficacy of oral metronidazole in *Demodex* eradication.

Few case-reports in rosacea showed conflicting results regarding the efficacy of oral metronidazole alone. Two cases out of three showed a marked reduction in the inflammatory picture, but not of the *Demodex* population (Schaller 2003; Pallotta 1998; Shelley 1989; Koçac 2002).

A small study reported a complete eradication of *Demodex folliculorum* in patients with rosacea treated with oral metronidazole, 500 mg during 20 days followed by 250 mg during 20 days (El Shazly 2004). Oral metronidazole has been studied on *Demodex* mainly in combination with other drugs.

A randomized, single-blind, controlled clinical trial compared the efficacy of oral ivermectin and combined therapy with oral ivermectin–metronidazole (dose 250 mg three times per day for 2 weeks) in 120 patients with treatment-resistant skin lesions and anterior blepharitis, and with proven *Demodex* infestation at skin and lashes levels. The combined therapy was superior in decreasing the mean count of *Demodex folliculorum* (Salem 2013).

## 4.2 TOPICAL TREATMENTS

Norn tested 45 different agents and found only a few could kill *Demodex* within several minutes in vitro—absolute alcohol, ether, xylol, benzene, Danish (sulfur-containing) ointment, dill weed oil, and caraway oil (Norn 1970). Other agents are able to kill *Demodex* in vitro in few minutes: 100% alcohol, 100% of essential dill weed oil and caraway oil. Unfortunately, these agents are not suitable for clinical use because of eye irritation (Gao 2005). Antiseptics such as povidone iodine are not able to kill *Demodex* either.

Clinically acceptable treatments range from techniques of lid cleansing to topically applied active ingredients.

### 4.2.1 LID HYGIENE

#### Standard eyelid hygiene

Standard eyelid hygiene is a basis for any eyelid pathology and has demonstrated some efficacy on *Demodex* count. But as far as a *Demodex* infestation is concerned, lid hygiene alone may be not sufficient first line treatment and should be considered to be an adjunctive treatment or to augment other treatments.

A study conducted in 60 patients with *Demodex*-related blepharitis compared the standard treatment of blepharitis for one month (antimicrobial, anti-allergic, non-steroidal therapy, plus artificial tears as required) to lid hygiene with sterile wipes impregnated with a micellar solution (Blephaclean®, lab. Théa) twice a day during 1 month (Figure 15). The comfort level improved better and faster in the hygiene group and the *Demodex* eradication was much greater in this group (Rykov 2017).

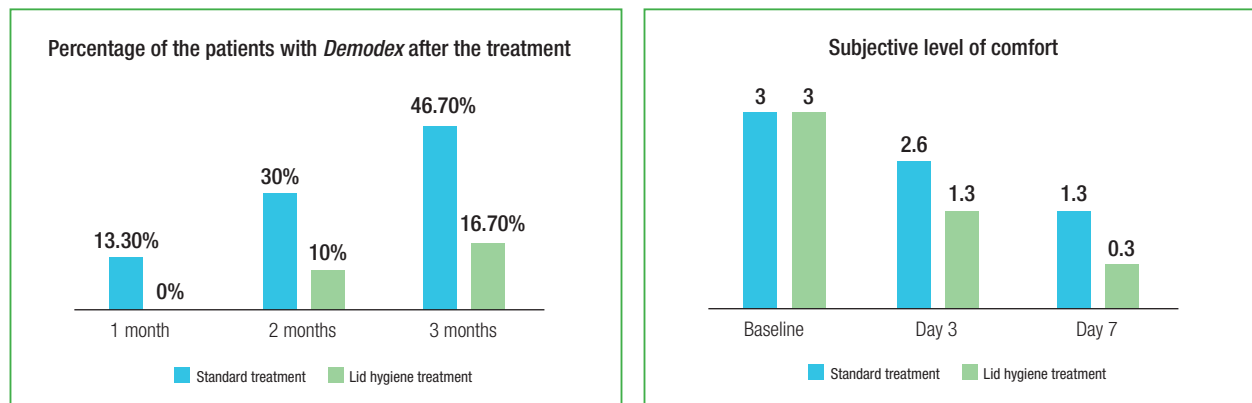


Figure 15: Efficacy of lid hygiene with sterile wipes impregnated with a micellar solution (from Rykov 2017)

### Baby shampoo

Lid hygiene with baby shampoo belongs to the traditional category for management of blepharitis. A very small group of patients (14 eyes) with *Demodex* and blepharitis was treated by washing the eyelids with 50% diluted baby shampoo on a cotton stick in the morning and evening during 3 months. Four eyes (28.6%) were described as having a 'total cure' of their blepharitis, five (37.5%) had partial improvement and five showed no change (Inceboz 2009). This poor result was confirmed by an in vitro study showing that 50% baby shampoo was not able to kill *Demodex* in 150 minutes (Gao 2005). The same study also concluded that 30 minutes pretreatment with 50% baby shampoo did not promote killing with other agents. In seven patients, an in vivo treatment with 50% baby shampoo during 1 to several months was able to reduce *Demodex* population in only 2 patients (Gao 2005).

Moreover, baby shampoo has been reported to be associated with a reduction in ocular surface MUC5AC levels, suggesting that it may have an adverse effect on goblet cell function.

A prospective, 4-week, randomized, double-masked, paired eye clinical trial, study compared baby shampoo to a dedicated eyelid cleanser (TheraTears™ SteriLid™) in patients with blepharitis. Clinical improvement was reported for both treatments, but the eyelid cleanser was preferred over baby shampoo by most patients. Improvements in the tear lipid layer, cylindrical collarettes, and inflammatory marker MMP-9 expression were observed only with the dedicated eyelid cleanser, as well as a greater decrease in dry eye symptoms score. Meibomian gland capping and MUC5AC expression worsened with baby shampoo treatment (Sung 2018).

### Lid scrubbing

Lid scrubbing has been used in many studies, combined with other topical treatments in most of them, mainly TTO of some form.

Scrubbing alone was used as a control group in a study on TTO efficacy in patients with ocular surface discomfort and positive result for *Demodex*: 54 patients applied lid scrubbing alone during 1 month. *Demodex* number did not decrease significantly, although OSDI score improved significantly but at a lesser extent than in the active treatment group (Koo 2012).

A specific device for lid scrubbing has been marketed under the brand BlephEx® (Rysurg, Tennessee, USA) to aid removal of the collarettes. This device has been reported to be effective together with TTO in two cases (Gunnarsdóttir 2016).



Figure 16: Lid scrubbing with BlephEx®

## 4.2.2 TOPICAL TREATMENT CONTAINING ACTIVE SUBSTANCES

### Ointments

A review of the literature mentions the efficacy of 'ointment treatment' made of mercury ointments, or sulphur of metronidazole gel (Czepita 2007). Indeed, a variety of ointments have been utilized historically for *Demodex* management: mercuric oxide ointment was reported to be effective, with occasional toxicity (Rodriguez 2005). Rodriguez reported a good efficacy of lid scrubbing associated with 2% mercury oxide ointment during 3 to 8

weeks on mites count, despite 'difficulty in its application and occasional toxicity' (Rodriguez 2005). However, mercuric oxide is no longer authorized.

Sulphur ointment has also shown some efficacy (Norn 1970; Rusiecka-Ziółkowska 2014).

To what extent the relative efficacy comes from the active ingredient or from the viscosity of ointment formulations remains unclear: indeed, the mercuric oxide ointment has been described as acting 'like a mechanically trap for the mites when they go out at night' (Gari-Toussaint 1993).

### **Topical metronidazole**

Topical metronidazole gel is known to improve clinical symptoms in chronic blepharitis (Arrúa 2015) and in rosacea (Parodi 2011). This effect may be related mainly to anti-inflammatory properties, but topical metronidazole 2% has been shown also to reduce the *Demodex* mite count (Czepita 2007). In chronic blepharitis, a study found that patients with *Demodex* showed a better improvement with metronidazole than patients whose blepharitis did not involve *Demodex* (Arrúa 2015). Metronidazole is marketed as a 0.75% concentration in various topical preparations indicated in rosacea. No marketed product for *Demodex* treatment, containing metronidazole for topical administration, exists.

49

### **Topical ivermectin**

As with metronidazole, topical ivermectin (10 mg/g) is indicated in the management of inflammatory forms of rosacea. Its efficacy is hypothesized to result from *Demodex* 'killing' together with anti-inflammatory properties (Schaller 2017). In rosacea, clinical studies showed superior efficacy and comparable safety of ivermectin 1% cream applied once daily during 12 to 16 weeks, as compared to vehicle control or to metronidazole 0.75% cream in the treatment of papulopustular rosacea (Cardwell 2016). No studies with topical ivermectin have been published in blepharitis yet.

### **Permethrin**

Permethrin is an insecticide used topically in the treatment of scabies and lice. Permethrin 5% cream is also indicated in papulopustular rosacea, and has been shown to significantly reduce the *Demodex* density and the severity of presentations in rosacea (Raoufinejad 2016). Previous studies found that permethrin 5% cream would be superior to metronidazole 0.75% gel in decreasing *Demodex folliculorum* infestation in papulopustular rosacea, and as effective as metronidazole 0.75% gel in treating skin erythema and papules (Koçac 2002).

### Pilocarpine

As organic phosphorus compounds used as insecticides against *Demodex* in dogs have a cholinesterase action, pilocarpine has been proposed as a possible treatment in human *Demodex* blepharitis (Norn 1970), but little evidence is available. In 32 eyes with blepharitis and *Demodex* infestation, 4% pilocarpine HCl gel applied by massaging in morning and evening for 1 month led to total cure of signs and symptoms in 37.5% of the eyes, partial improvement in 40.6% and no result in the remaining eyes (Inceboz 2009). Another study in a small group of 11 people (with ocular discomfort and abundant *Demodex*) compared 4% pilocarpine in one eye, the contralateral eye being used as a control. Mite numbers were significantly reduced by the treatment. The mite reduction was closely correlated with the extent to which itching was alleviated (Foulk 1996). In vitro, 4% pilocarpine did not succeed in killing *Demodex* in 150 minutes (Gao 2005).

### Topical antibiotics

There is no evidence of efficacy of antibiotics on *Demodex*. Norn tested in vitro several antimycotics, antibiotics and povidone iodine at usual concentrations, with no effect on *Demodex* mites survival (Norn 1970).

Arrúa compared the efficacy of several treatments in chronic blepharitis and reported a less improvement with lid hygiene + topical antibiotic + steroid treatment than with lid hygiene alone or lid hygiene + topical metronidazole (Arrúa 2015).

### Tea tree oil (TTO)

TTO is a natural essential oil, steam distilled from the leaf of an Australian native plant, *Melaleuca alternifolia*, which has antibacterial, antifungal, anti-inflammatory and acaricidal properties (Figure 17).



Figure 17: Tea tree

TTO competitively blocks the neurotransmitter acetylcholinesterase. This may contribute to its arthropodicidal effect, with a strong potency related to a possible synergistic or additive effect of several of its components (Lam 2018).

The chitinous exoskeleton of *Demodex* may activate the inflammatory cascade in keratinocytes, and infestation by *Demodex* mites increases tear cytokine levels, which can cause inflammation of the lid margin and ocular surface. TTO, and specifically one of its major components terpinen-4-ol (T4O), exhibits potent inhibition of substance P-related inflammation and liposaccharide-induced cytokines such as IL-1 $\beta$ , IL-6 and IL-10 produced by macrophages. TTO can reduce the production of superoxide ions, of pro-inflammatory factors such as TNF, IL-1, IL-8 and PGE2 in monocytes and modulate vasodilation and plasma extravasation associated with histamine induced inflammation in human (Lam 2018).

TTO lipophilic properties could disrupt membranes, accounting for its antimicrobial properties. *Demodex* is suspected to bring in *Staphylococcus* and *Streptococcus* and their superantigens may play a role in *Demodex*-related rosacea. Therefore, the anti-microbial properties of TTO are an important aspect in managing *Demodex* infestation (Lam 2018).

TTO has been shown in vitro to be able to kill *Demodex* in a dose-dependent manner, at 25%, 50% and 100% concentrations. In vivo, 5 minutes lid scrub with 50% TTO removes dandruff from the lash root, and also stimulates *Demodex* to migrate from cylindrical dandruff. If practiced only once, lid scrub with 50% TTO does not prevent cylindrical dandruff to return in 1 week, probably by not killing the *Demodex* buried deep in the skin. A prolonged and more aggressive treatment by weekly lid scrub with 50% TTO followed by daily home lid scrub with TTO shampoo leads the *Demodex* count to drop to zero within 3 to 4 weeks without any recurrence 1 month later in most patients (Gao 2005) (Figure 18).

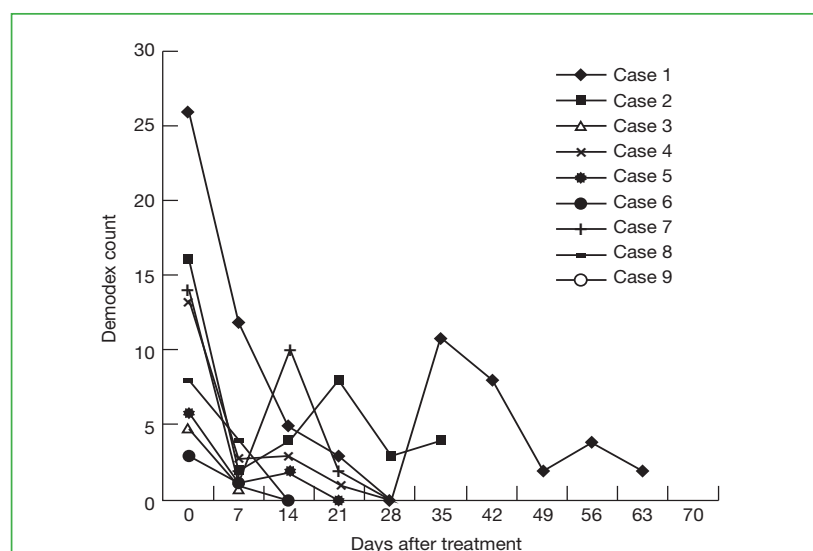


Figure 18: *Demodex* count in patients receiving weekly TTO lid scrub plus daily lid scrub with TTO shampoo (from Gao 2005).

50% TTO has also been shown to be effective in alleviating ocular symptoms and inflammation of the lids and ocular surface, in stabilizing the tear film and in improving the visual acuity in *Demodex* patients (Gao 2012).

A randomized study on 160 patients with ocular discomfort associated with ocular *Demodex* infestation showed that a 4-week treatment (weekly lid scrub with 50% TTO and daily lid scrub with 5 to 10% TTO) reduces significantly the *Demodex* count and the ocular discomfort compared to eyelid scrub without TTO (Koo 2012) (Figure 19).

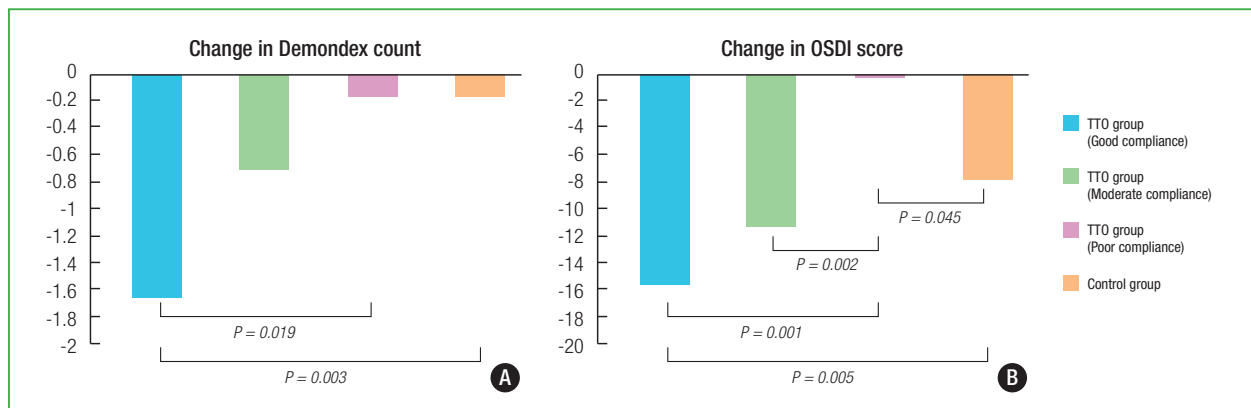


Figure 19: Change in Demodex count (A) and OSDI score (B) after eyelid scrub in TTO group and control group (from Koo 2012).

As 50% TTO is noticeable irritating for some patients; indeed the same author found in a subsequent study that a 4-week treatment with twice daily lid scrubbing using only 5% TTO led to a similar decrease in mites count and ocular itching (Gao 2007).

Another study investigated the effect of twice daily lid scrubbing with 7% TTO mixed with a lid hygiene solution (Blephasol®, lab. Théa) in 72 patients with blepharitis and *Demodex* infestation. After 2 month-treatment, in the patients with more than 4 *Demodex* mites per lash at baseline, the *Demodex* count decreased significantly as well as the OSDI score. Corneal erosion developed in 1.3% of the patients, which healed after cessation of the treatment (Kim 2012).

### KEY POINTS

- *In vitro* studies showed that TTO can kill *Demodex* mites.
- Clinical studies demonstrated the efficacy of TTO to improve patients ocular symptoms and to reduce the number of mites.
- However, tolerability of TTO could be an issue.



### Terpinen-4-ol: the most active part of TTO

Natural TTO contains approximately 100 constituents, but commercial TTO is regulated by the International Organization for Standardization (ISO4730:2004) and must contain a specific range of 15 major ingredients to be known as TTO. The thirteen most abundant out of those 15 ingredients have been tested individually on *Demodex* mites in vitro, at concentrations ranging from 1% to 100%, for up to 150 minutes (Tighe 2013). Six out of thirteen were considered as ineffective, as they had no killing action below a 25% concentration (Tighe 2013).

Among the remaining seven, T4O has been found to be the most potent ingredient of TTO to kill *Demodex*, and the only one that remained effective, with an in vitro killing effect on *Demodex*, at a concentration of 1%. The mean survival time of the mites was 12.3 minutes for a 10% concentration, 32.1 minutes for a 5% concentration and 87.6 minutes for the lowest 1% concentration (Tighe 2013).

Additionally, T4O possesses anti-inflammatory properties by suppressing superoxide production and proinflammatory cytokines such as TNF- $\alpha$ , IL-1 $\beta$ , PGE2, providing clinical improvement of ocular irritation and inflammatory signs and vision. Furthermore, tear film stabilization has been observed in some patients, presumably due to improvement of meibum lipid production (Tighe 2013).

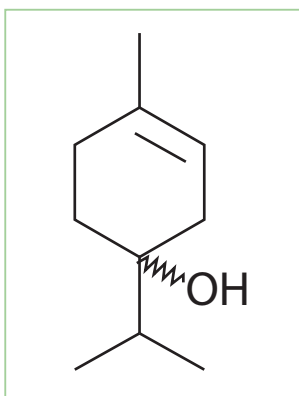


Figure 20: Terpinen-4-ol



Figure 21: Tea tree oil

Isolation from the other allergenic and ineffective ingredients should be able to reduce irritation and allergic reactions that have been reported for general TTO in previous studies.

Lid hygiene wipes containing T4O have been marketed, with a recommended treatment regimen of one or two daily applications of T4O during 6 to 8 weeks to cover 2 *Demodex* life cycles, and to prevent re-infestation (Cheng 2015). A study performed in 50 patients with MGD showed a good ability of all patients to use correctly the wipes after a single demonstration by either a live teaching or a video tutorial. The acceptability was good,

with a mean comfort level of 4 on a 6 point-scale. The stinging score was 2 on a 4 point-scale, absent or mild in 52% of the patients and more severe but temporary in most other patients. Only 1 patient out of 50 complained of intolerable stinging (Qiu 2018).

A multicentre, open, randomised study on 49 patients was conducted to evaluate and compare the performance of two therapeutic schemes (one daily application vs two daily applications) of sterile wipes containing sodium hyaluronate and terpinen-4-ol (Blephademodex®, lab. Théa) in improving the ocular symptoms and signs in patients suffering from *Demodex*-associated blepharitis. Another objective of this study was to evaluate the tolerance/safety of the cleansing wipes applied to the eyelids and base of eyelashes.

The patients used the product for one month (29 days) and were randomised into two distinct groups of therapeutic scheme: patients of Group 1 used the wipes once daily and patients of Group 2 used them twice daily. An intermediate visit was planned after one week of treatment (Visit 2 on Day 8).

Overall ocular discomfort was reduced from baseline to Day 29 in Group 1 ( $-5.7 \pm 0.4$ ,  $p < 0.0001$ ) and Group 2 ( $-6.8 \pm 0.7$ ,  $p < 0.0001$ ) (Figure 22). Improvements were observed as soon as Day 8 in both groups ( $p < 0.0001$ ). The between-group differences were not statistically significant.

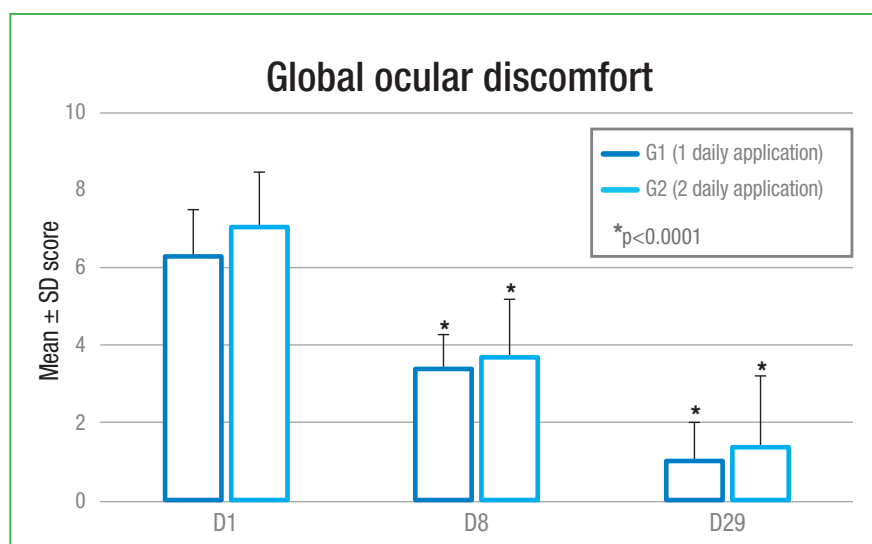


Figure 22: Efficacy of the cleansing wipes on global ocular discomfort

Thus, the cleansing wipes was effective in reducing the global ocular discomfort in patients with *Demodex* blepharitis, regardless of the therapeutic scheme used (one or two daily applications).

The major secondary performance criterion was the eyelid margin hyperaemia, as evaluated by the investigator on a 4-point scale.

After 29 days of treatment, the eyelid margin hyperaemia score was significantly decreased in both groups of therapeutic scheme: from 1.5 to 0.4 ( $-1.1$ ,  $p < 0.0001$ ) in Group 1 and from 1.6 to 0.5 ( $-1.1$ ,  $p < 0.0001$ ) in Group 2 (Figure 23). Patients having moderate and severe hyperaemia at baseline no longer experienced eyelid margin hyperaemia whatever the dose regimen at Day 29. No statistically significant difference was found between the two groups, indicating the absence of impact of the therapeutic scheme used (one vs two daily applications) on this parameter.

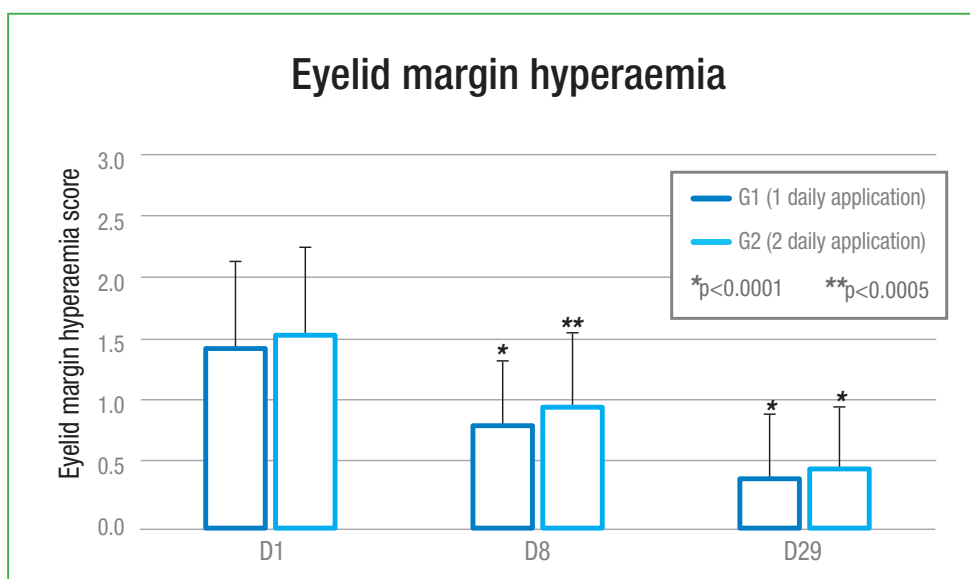


Figure 23: Efficacy of the cleansing wipes on eyelid margin hyperaemia

All the following other performance criteria were also improved after 29 days of treatment in both groups of therapeutic schemes:

- ▶ Ocular symptoms associated with *Demodex* blepharitis: itching, burning/stinging sticky eye in the morning, fluctuating blurred vision, light sensitivity, foreign body sensation, others.
- ▶ Mean number of cylindrical dandruff.
- ▶ Ocular signs: abnormal eyelashes aspect, eyelid oedema, conjunctival hyperaemia, conjunctival discharge, corneal fluorescein staining.

The improvements seemed slightly more pronounced in Group 2 compared to Group 1.

The number of cylindrical dandruff was highly reduced after 29 days of treatment. At the end of the study, a decrease of  $10.7 (\pm 9.8)$  dandruff was observed in Group 1 versus  $16.3 (\pm 11.8)$  dandruff in Group 2 (Figure 24). At Day 29, 30.4% of patients in Group 1 vs 43.5% in Group 2 did not have any cylindrical dandruff.

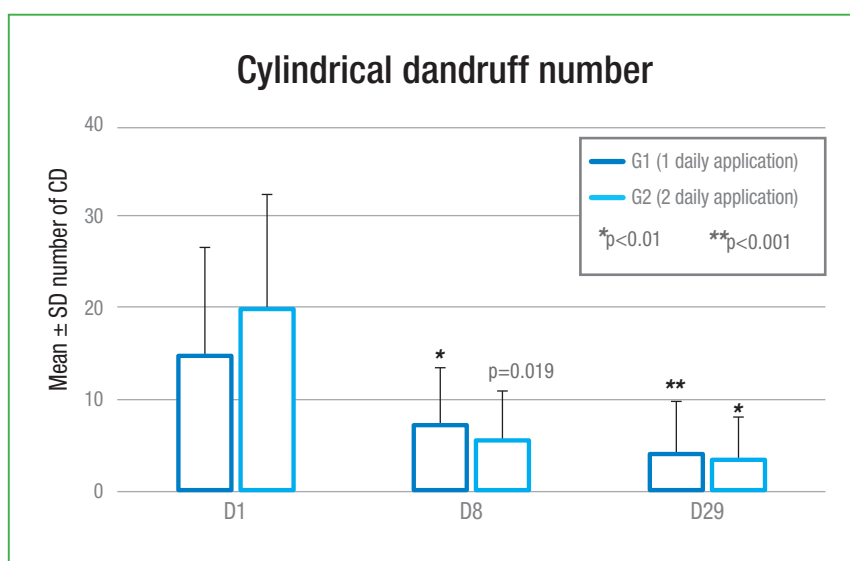


Figure 24: Efficacy of the cleansing wipes on the number of cylindrical dandruff

To conclude, these cleansing wipes containing sodium hyaluronate and terpinen-4-ol applied once (morning) or twice (morning and evening) daily were shown to be effective in patients suffering from *Demodex*-associated blepharitis:

- In reducing the global ocular discomfort in patients with *Demodex* blepharitis.
- In decreasing the mean number of cylindrical dandruff and other ocular symptoms and signs after 29 days of treatment.
- In improving the eyelid margin hyperaemia.

Moreover, these cleansing wipes were well tolerated by the patients.

### 4.3 SHOULD WE AIM FOR TOTAL ERADICATION?

Symptomatic *Demodex* disease probably results from an imbalance in the ecology of the external eye. Treatment should not aim to totally eradicate the mite, but rather to restore the ocular ecology to a balanced state (Nicholls 2017).

As demonstrated in most of the above-mentioned studies, clinical relief and objective improvement may be obtained with a simple reduction in the mite population. Furthermore, a retrospective data analysis from 2015 reported a low rate of eradication by all individual therapeutic options, namely TTO 5% ointment once a day, 0.05% TTO lids and face skin cleansing, 2% metronidazole ointment, oral metronidazole 500 mg twice daily for 10 days or oral ivermectin 6 mg twice in 15 days. But in this study, the clinical effect on symptoms was much higher than the eradication rate, supporting the concept that reducing the

mite count may be more important than a complete eradication (Hirsch-Hoffmann 2015).


Thus, total eradication is unnecessary and may even be counterproductive as *Demodex* is probably part of the normal ocular ecology.

Treatment	Evidence level	Efficacy on mites count	Efficacy on symptoms	Recommended dosage or used dosage in studies
Oral ivermectin	Strong	+++	+++	200 µg per kilogram of body weight in single dose, possibly repeated after 2 weeks
Oral metronidazole	Weak	±	++	250 mg three times per day for 2 weeks
Lid scrubbing	Weak	-	±	Twice a day
Lid hygiene with cleansing solution	Strong	+	+	Lid hygiene twice a day with sterile wipes impregnated with a micellar solution x 1 month
Lid hygiene with baby shampoo	Weak	-	±	2 or 3 times a day
Topical mercury ointment	Weak	±	±	Not currently authorized
Topical sulphur ointment	Weak	-	±	?
Topical ivermectin	Strong	++	++	Topical application once a day x 12 to 16 weeks
Topical metronidazole	Mild	+	+	Topical application twice a day x 2 months.
Permethrin	Mild	++	++	Topical application twice daily x 12 weeks
Pilocarpine	Weak	-	+	
Antibiotics	Weak	-	-	
Steroids	Weak	-	-	
Tea tree oil	Strong	+++	+++	5 to 10% TTO applied topically twice a day x 1 to 2 months
Terpinen-4-ol	Mild	+++		1%

Table 5: *Demodex* tested treatments: synthesis

### KEY POINTS

- ‘Over 200 chemicals and compounds have been used by various investigators on Demodicosis. Quite likely all have been effective to some degree, because anything which cleanses the mouth of the follicle upsets the ecology and reduces the number of mites’ (quoted from Coston 1967).
- Indeed, various agents have been reported to provide a limited efficacy in sparse clinical studies, most of which were of mediocre methodology.
- Recently, studies conducted with modern methodology were able to demonstrate an undisputable activity of several agents (Table 5).
- Topical TTO and oral ivermectin are now well established as reference treatments on *Demodex* count and on related blepharitis.
- Nonetheless, in *Demodex*-related blepharitis, lid hygiene may be considered as maintenance treatment after a specific first line treatment for *Demodex*.



# 5

## WHO TO TREAT, AND WHEN?

*Demodex* is a skin commensal, which is present under normal physiological conditions, but the role of *Demodex* in blepharitis should not be overlooked.

*Demodex* infestation alone, if no clinical signs and/or symptoms are associated, does not warrant treatment (Nicholls 2017). Conversely, clinical signs of ocular inflammation without overload of *Demodex* are likely unrelated to *Demodex* and the treatment should address other possible pathophysiological etiologies. Many patients will respond well to primary care and will not require antidemodetic treatment.

But in patients with chronic ocular surface or lids pathologies resistant to primary treatments, *Demodex* is under-recognised, under-diagnosed and under-treated.

In such patients, showing persistent symptoms despite appropriate treatment of underlying eye pathologies, *Demodex* should be searched and, in case of an overpopulation, a specific anti-*Demodex* treatment should be initiated (Nicholls 2017). Treatment with standard lid hygiene may also be recommended. In case of symptomatic recurrence with proven *Demodex* infestation, subsequent courses of anti-*Demodex* treatment should be commenced.

As with all ocular surface diseases (OSD), there is an optimal balance between efficacy and tolerability in treatments.

There is no point in addressing a pathological issue while creating another with an inappropriate treatment, especially when the inflamed or damaged ocular surface is vulnerable and likely to be further compromised by aggressive treatments.

This is why many compounds which have a potent killing effect on *Demodex* cannot be used in clinical practice, because of the eye irritation they cause (such as 100% alcohol, 100% of essential dill weed oil and caraway oil).

We can therefore suggest some general safety rules for *Demodex* treatment:

- ▶ Treat only patients with symptoms refractory to usual first line measures (lid hygiene, artificial tears, withdrawal of all preserved eye drops).
- ▶ For first-line treatment, select the most efficient treatments with good tolerability: currently, TTO has the highest efficacy with good ocular and systemic tolerability. Use oral ivermectin (0.2 mgs/Kg) if TTO is not sufficient to improve symptoms.
- ▶ Do not use preserved-treatments.
- ▶ Use the minimum efficient dosage: TTO provides a similar efficacy with a 50% or 5-7% concentration, but a better tolerability at lowest concentrations.



- Use the minimum efficient duration: oral ivermectin is used in single administration, repeated after 2 weeks. TTO-containing treatment is recommended during 1 to 2 months, depending on symptoms alleviation.
- Switch to maintenance treatment as soon as symptoms are controlled: lid hygiene twice a day with gentle products.
- Retreat only if symptoms reappear with re-increased mite count.

STEPS	BLEPHARITIS TREATMENTS
1.	First line treatment (lid hygiene, artificial tears, withdrawal of preserved eye drops)
2.	If resistant: search for <i>Demodex</i> mites
3.	If proven <i>Demodex</i> infestation: topically applied TTO-containing product during 28 days
4.	If it is not sufficient to improve symptoms: add oral ivermectin, 200 µg per kilogram of body weight in single dose, possibly repeated after 2 weeks
5.	Maintenance treatment with daily lid hygiene
6.	In case of blepharitis recurrence, restart to point 2

Table 6: Management of *Demodex* blepharitis in 6 steps

### KEY POINTS

- Many treatments have been tested against *Demodex*, most of them with a weak level of evidence and a poor efficacy.
- Only topical TTO and oral ivermectin have shown a real efficacy against *Demodex*, with reasonable tolerability.
- A specific treatment against *Demodex* should be started in patients with chronic or recurrent blepharitis resistant to first line treatments (lid hygiene, artificial tears, withdrawal of preserved eyedrops) and with proven infestation.
- Lid hygiene shall be considered as permanent, ongoing maintenance treatment after the end of the anti-demodectic treatment.



---

# 6

---

## **CLINICAL FAQS HANDY REFERENCE GUIDE**

**Do mites come back – When should we re-treat?**

*Demodex* is a commensal of the skin, comparable to *Staphylococcus*. It is thus normally present in small amounts on the skin and lids, and may become invasive under certain conditions. Re-infestation after successful treatment is possible if these conditions persist: poor hygiene, immunodeficiency, etc. Re-treatment may be necessary when the infestation is again associated with symptoms resisting to primary care. In patients with recurrent symptomatic infestations, it may be proposed to maintain a regular lid hygiene with lid wipes impregnated with TTO or with a gentle cleansing solution, such as micellar solution.

**Is standard lid hygiene enough?**

As shown by Rykov (2016), standard lid hygiene may be enough to resolve ocular discomfort and blepharitis with *Demodex* infestation. Thus, we suggest that *Demodex* should be searched and, if found in excess, specifically treated only in blepharitis and/or ocular surface inflammation resistant to basic treatment by lid hygiene. A relay treatment with standard lid hygiene should be maintained after the end of the anti-*Demodex* treatment.

**When to treat?**

*Demodex* should be specifically treated only in blepharitis and/or ocular surface inflammation resistant to primary treatment by lid hygiene and ocular lubricants, with a positive identification of *Demodex* infestation.

**What is risk of not treating?**

Chronic infestation of the lash follicles may lead to misdirection of lashes, trichiasis and ultimately madarosis, conjunctival and corneal inflammation and keratitis. *Demodex* blepharitis should certainly be considered as a potential cause of refractory blepharoconjunctivitis.

**Do steroids help?**

There is no evidence of steroid efficacy on *Demodex*. Conversely, steroids may depress local immunity and increase the skin ecosystem imbalance, and thus increase the risk of infection.

**Do topical antibiotics help?**

There is no evidence of topical antibiotics efficacy. Furthermore, the use of topical antibiotics may cause an imbalance of the the ocular lid flora involving saprophytic bacteria and promote bacterial or viral infections.

**Can you catch *Demodex* from animals?**

Pets like dogs may be mostly infected by *Demodex canis*, which is a different species not found in human, but also by *Demodex folliculorum* (Tsai 2010). But in any case, humans do not 'catch' *Demodex folliculorum*, as the mite is a commensal. That means that like *Staphylococcus* or *Candida*, it is normally present on the human skin, part of the skin ecological system, and not harmful when in small physiological amount. *Demodex* may contribute to ocular surface pathologies only when its population is overgrowing. A study failed to find any correlation between pet owning and *Demodex* infestation (Inceboz, 2009).

**Do you need to treat the whole face/body?**

As *Demodex* is naturally present on the skin, and as only a reduction of the lid overpopulation is requested to alleviate the symptoms, only the lids shall be treated.

**Can you use vaseline or paraffin ointment to smother *Demodex* like we do for crab (pubic) lice?**

Much easier treatments are available for *Demodex*: twice a day lid cleaning with wipes containing purified TTO during 1 month is enough to bring the mite population back to normal.

**Can/should we eradicate them?**

It is not necessary to eradicate *Demodex* to resolve symptoms, but only to reduce the overpopulation of mites and bring it back to normal.

**Is tea tree oil safe?**

5 or 7% TTO is safe and does not induce any reaction in most patients. Some mild eye irritation may occur in few patients, and resolve after the end of the treatment.

Furthermore, new products are based only on the most efficient compound of TTO (purified T4O) and thus eliminate most irritating compounds present in native TTO.

# REFERENCES

---

1. Alver O, Kivanc SA, Akova BB, Tuzemen NU, Ener B, Ozmen AT. A Clinical Scoring System for Diagnosis of Ocular Demodicosis. *Med Sci Monit* 2017; 23: 5862-5869.
2. Andrews JR. The prevalence of hair follicle mites in caucasian New Zealanders. *N Z Med J* 1982; 95 (711): 451-453.
3. Arrua M, Samudio M, Farina N, Cibils D, Laspina F, Sanabria R, Carpinelli L, Mino De KH. Comparative study of the efficacy of different treatment options in patients with chronic blepharitis. *Arch Soc Esp Oftalmol* 2015; 90 (3): 112-118.
4. Aylesworth R, Vance JC. *Demodex folliculorum* and *Demodex brevis* in cutaneous biopsies. *J Am Acad Dermatol* 1982; 7 (5): 583-589.
5. Aytakin S, Yasar S, Goktay F, Gunes P. Spontaneous fluorescence of *Demodex* in the dark. *J Eur Acad Dermatol Venereol* 2016; 30 (2): 359-360.
6. Basta-Juzbasic A, Subic JS, Ljubojevic S. *Demodex folliculorum* in development of dermatitis rosaceiformis steroidica and rosacea-related diseases. *Clin Dermatol* 2002; 20 (2): 135-140.
7. Baudouin C, Messmer EM, Aragona P, Geerling G, Akova YA, Benítez-del-Castillo J, Boboridis KG, Merayo-Llodes J, Rolando M, Labetoulle M. Revisiting the vicious circle of dry eye disease: a focus on the pathophysiology of meibomian gland dysfunction. *Br J Ophthalmol* 2016; 100 (3): 300-6.
8. Bhandari V, Reddy JK. Blepharitis: always remember *Demodex*. *Middle East Afr J Ophthalmol* 2014; 21 (4): 317-320.
9. Bonnar E, Eustace P, Powell FC. The *Demodex* mite population in rosacea. *J Am Acad Dermatol* 1993; 28 (3): 443-448.
10. Brown M, Hernandez-Martin A, Clement A, Colmenero I, Torrelo A. Severe *Demodex folliculorum*-associated oculocutaneous rosacea in a girl successfully treated with ivermectin. *JAMA Dermatol* 2014; 150 (1): 61-63.
11. Canti G. Demonstration of *Demodex Folliculorum*. *Cytopathology* 2010; 21 (5): 347-348.
12. Cardwell LA, Alinia H, Moradi TS, Feldman SR. New developments in the treatment of rosacea - role of once-daily ivermectin cream. *Clin Cosmet Investig Dermatol* 2016; 9: 71-77.
13. Chen W, Plewig G. Are *Demodex* mites principal, conspirator, accomplice, witness or bystander in the cause of rosacea? *Am J Clin Dermatol* 2015; 16 (2): 67-72.
14. Chen W, Plewig G. Human demodicosis: revisit and a proposed classification. *Br J Dermatol* 2014; 170 (6): 1219-1225.
15. Cheng AM, Sheha H, Tseng SC. Recent advances on ocular *Demodex* infestation. *Curr Opin Ophthalmol* 2015; 26 (4): 295-300.
16. Coston TO. *Demodex folliculorum* blepharitis. *Trans Am Ophthalmol Soc* 1967; 65: 361-392.
17. Czepita D, Kuzna-Grygiel W, Czepita M, Grobelny A. *Demodex folliculorum* and *Demodex brevis* as a cause of chronic marginal blepharitis. *Ann Acad Med Stetin* 2007; 53 (1): 63-67.
18. Damian D, Rogers M. *Demodex* infestation in a child with leukaemia: treatment with ivermectin and permethrin. *Int J Dermatol* 2003; 42 (9): 724-726.

19. El-Shazly AM, Hassan AA, Soliman M, Morsy GH, Morsy TA. Treatment of human *Demodex* folliculorum by camphor oil and metronidazole. J Egypt Soc Parasitol 2004; 34 (1): 107-116.
20. Elston DM. *Demodex* mites: facts and controversies. Clin Dermatol 2010; 28 (5): 502-504.
21. English FP. Variant of *Demodex* folliculorum infesting the eyelids. Br J Ophthalmol 1971; 55 (11): 747-749.
22. Filho PA, Hazarbassanov RM, Grisolia AB, Pazos HB, Kaiserman I, Gomes JA. The efficacy of oral ivermectin for the treatment of chronic blepharitis in patients tested positive for *Demodex* spp. Br J Ophthalmol 2011; 95 (6): 893-895.
23. Forton F. *Demodex* et inflammation périfolliculaire chez l'homme : Revue et observation de 69 biopsies. Ann Dermatol Venereol 1986; 113 (11): 1047-1058.
24. Forton FM, De M, V. Two Consecutive Standardized Skin Surface Biopsies: An Improved Sampling Method to Evaluate *Demodex* Density as a Diagnostic Tool for Rosacea and Demodicosis. Acta Derm Venereol 2017; 97 (2): 242-248.
25. Fulk GW, Murphy B, Robins MD. Pilocarpine gel for the treatment of demodicosis--a case series. Optom Vis Sci 1996; 73 (12): 742-745.
26. Gao YY, Di Pascuale MA, Elizondo A, Tseng SC. Clinical treatment of ocular demodocosis by lid scrub with tea tree oil. Cornea 2007; 26 (2): 136-143.
27. Gao YY, Di Pascuale MA, Li W, Liu DT, Baradaran-Rafii A, Elizondo A, Kawakita T, Raju VK, Tseng SC. High prevalence of *Demodex* in eyelashes with cylindrical dandruff. Invest Ophthalmol Vis Sci 2005; 46 (9): 3089-3094.
28. Gao YY, Di Pascuale MA, Li W, Baradaran-Rafii A, Elizondo A, Kuo CL, Raju VK, Tseng SC. In vitro and in vivo killing of ocular *Demodex* by tea tree oil. Br J Ophthalmol 2005; 89 (11): 1468-1473.
29. Gao YY, Xu DL, Huang I, Wang R, Tseng SC. Treatment of ocular itching associated with ocular demodicosis by 5% tea tree oil ointment. Cornea 2012; 31 (1): 14-17.
30. Gari-Toussaint M, Larmande J, Baudouin C, Le Fichoux Y, Gaxotte P. Action de l'ivermectine sur *Demodex* folliculorum au cours des blépharites et conjonctivites chroniques chez l'homme = Action of ivermectin on *Demodex* folliculorum in human blepharitis and conjunctivitis. Bull Société Fr Parasitologie 1993; 11 (2): 271-273.
31. Gonzalez-Hinojosa D, Jaime-Villalonga A, Aguilar-Montes G, Lammoglia-Ordiales L. *Demodex* and rosacea: Is there a relationship? Indian J Ophthalmol 2018; 66 (1): 36-38.
32. Grice EA, Segre JA. The skin microbiome. Nat Rev Microbiol 2011; 9 (4): 244-253.
33. Gunnarsdottir S, Kristmundsson A, Freeman MA, Bjornsson OM, Zoega GM. *Demodex* folliculorum, hársekkjamítill, dulin orsök hvarmabólgu. Laeknabladid 2016; 102 (5): 231-235.
34. Hirsch-Hoffmann S, Kaufmann C, Banninger PB, Thiel MA. Treatment options for *Demodex* blepharitis: patient choice and efficacy. Klin Monbl Augenheilkd 2015; 232 (4): 384-387.
35. Holzchuh FG, Hida RY, Moscovici BK, Villa Albers MB, Santo RM, Kara-Jose N, Holzchuh R. Clinical treatment of ocular *Demodex* folliculorum by systemic ivermectin. Am J Ophthalmol 2011; 151 (6): 1030-1034.
36. Hom MM, Mastrotta KM, Schachter SE. *Demodex*: Clinical Cases and Diagnostic Protocol. Optom Vis Sci 2013; 90 (7): e198-e205.

37. Hu Q, Wang Y. [Investigation on the prevalence of human *Demodex* among 2,248 medical students in inner Mongolia]. Zhongguo Ji Sheng Chong Xue Yu Ji Sheng Chong Bing Za Zhi 2001; 19 (4): 239-240. Abstract only.
38. Inceboz T, Yaman A, Over L, Ozturk AT, Akisu C. Diagnosis and treatment of demodectic blepharitis. Turkiye Parazit Derg 2009; 33 (1): 32-36.
39. Jalbert I, Rejab S. Increased numbers of *Demodex* in contact lens wearers. Optom Vis Sci 2015; 92 (6): 671-678.
40. Jarmuda S, McMahon F, Zaba R, O'Reilly N, Jakubowicz O, Holland A, Szkaradkiewicz A, Kavanagh K. Correlation between serum reactivity to *Demodex*-associated *Bacillus oleronius* proteins, and altered sebum levels and *Demodex* populations in erythematotelangiectatic rosacea patients. J Med Microbiol 2014; 63 (Pt 2): 258-262.
41. Jones L, Downie LE, Korb D, Benitez-del-Castillo JM, Dana R, Deng SX, Dong PN, Geerling G, Hida RY, Liu Y, Seo KY, Tauber J, Wakamatsu TH, Xu J, Wolffsohn JS et al. TFOS DEWS II Management and Therapy Report. Ocul Surf 2017; 15 (3): 575-628.
42. Kabatas N, Dogan AS, Kabatas EU, Acar M, Bicer T, Gurdal C. The Effect of *Demodex* Infestation on Blepharitis and the Ocular Symptoms. Eye Contact Lens 2017; 43 (1): 64-67.
43. Karıncaoglu Y, Tepe B, Kalayci B, Atambay M, Seyhan M. Is *Demodex folliculorum* an aetiological factor in seborrhoeic dermatitis? Clin Exp Dermatol 2009; 34 (8): e516-e520.
44. Kasetsuwan N, Kositphipat K, Busayarat M, Threekhan P, Preativatanyou K, Phumee A, Siriyasatien P. Prevalence of ocular demodicosis among patients at Tertiary Care Center, Bangkok, Thailand. Int J Ophthalmol 2017; 10 (1): 122-127.
45. Kaya S, Selimoglu MA, Kaya OA, Ozgen U. Prevalence of *Demodex folliculorum* and *Demodex brevis* in childhood malnutrition and malignancy. Pediatr Int 2013; 55 (1): 85-89.
46. Kemal M, Sumer Z, Toker MI, Erdogan H, Topalkara A, Akbulut M. The Prevalence of *Demodex folliculorum* in blepharitis patients and the normal population. Ophthalmic Epidemiol 2005; 12 (4): 287-290.
47. Kheirkhah A, Casas V, Li W, Raju VK, Tseng SC. Corneal manifestations of ocular *Demodex* infestation. Am J Ophthalmol 2007; 143 (5): 743-749.
48. Kheirkhah A, Blanco G, Casas V, Tseng SC. Fluorescein dye improves microscopic evaluation and counting of *Demodex* in blepharitis with cylindrical dandruff. Cornea 2007; 26 (6): 697-700.
49. Kim JH, Chun YS, Kim JC. Clinical and immunological responses in ocular demodocosis. J Korean Med Sci 2011; 26 (9): 1231-1237.
50. Kim JT, Lee SH, Chun YS, Kim JC. Tear cytokines and chemokines in patients with *Demodex* blepharitis. Cytokine 2011; 53 (1): 94-99.
51. Kim YW, Kim M, Wee WR. Effect of 7% tea-tree oil lid scrub on the *Demodex* blepharitis. ARVO. Fort Lauderdale, USA, May 6-10, 2012. 2012; E-Abstract 611/A79.
52. Kocak M, Yagli S, Vahapoglu G, Eksioglu M. Permethrin 5% cream versus metronidazole 0.75% gel for the treatment of papulopustular rosacea. A randomized double-blind placebo-controlled study. Dermatology 2002; 205 (3): 265-270.



53. Koo H, Kim TH, Kim KW, Wee SW, Chun YS, Kim JC. Ocular surface discomfort and *Demodex*: effect of tea tree oil eyelid scrub in *Demodex* blepharitis. J Korean Med Sci 2012; 27 (12): 1574-1579.
54. Kulac M, Ciftci IH, Karaca S, Cetinkaya Z. Clinical importance of *Demodex* folliculorum in patients receiving phototherapy. Int J Dermatol 2008; 47 (1): 72-77.
55. Kumar A, Karthikeyan K. Madarosis: a marker of many maladies. Int J Trichology 2012; 4 (1): 3-18.
56. Lacey N, Ni RS, Powell FC. *Demodex* mites--commensals, parasites or mutualistic organisms? Dermatology 2011; 222 (2): 128-130.
57. Lacey N, Kavanagh K, Tseng SC. Under the lash: *Demodex* mites in human diseases. Biochem (Lond) 2009; 31 (4): 2-6.
58. Lam NSK, Long XX, Griffin RC, Chen MK, Doery JC. Can the tea tree oil (Australian native plant: *Melaleuca alternifolia* Cheel) be an alternative treatment for human demodicosis on skin? Parasitology 2018; In Press.
59. Lee SH, Chun YS, Kim JH, Kim ES, Kim JC. The Relationship Between *Demodex* and Ocular Discomfort. Invest Ophthalmol Vis Sci 2010; 51 (6): 2906-2911.
60. Li J, O'Reilly N, Sheha H, Katz R, Raju VK, Kavanagh K, Tseng SC. Correlation between ocular *Demodex* infestation and serum immunoreactivity to *Bacillus* proteins in patients with Facial rosacea. Ophthalmology 2010; 117 (5): 870-877.
61. Liang H, Randon M, Michee S, Tahiri R, Labbe A, Baudouin C. In vivo confocal microscopy evaluation of ocular and cutaneous alterations in patients with rosacea. Br J Ophthalmol 2017; 101 (3): 268-274.
62. Liang L, Ding X, Tseng SC. High prevalence of *Demodex* brevis infestation in chalazia. Am J Ophthalmol 2014; 157 (2): 342-348.
63. Liang L, Safran S, Gao Y, Sheha H, Raju VK, Tseng SC. Ocular demodicosis as a potential cause of pediatric blepharoconjunctivitis. Cornea 2010; 29 (12): 1386-1391.
64. Litwin D, Chen W, Dzika E, Korycinska J. Human Permanent Ectoparasites; Recent Advances on Biology and Clinical Significance of *Demodex* Mites: Narrative Review Article. Iran J Parasitol 2017; 12 (1): 12-21.
65. Liu J, Sheha H, Tseng SC. Pathogenic role of *Demodex* mites in blepharitis. Curr Opin Allergy Clin Immunol 2010; 10 (5): 505-510.
66. Luo X, Li J, Chen C, Tseng S, Liang L. Ocular Demodicosis as a Potential Cause of Ocular Surface Inflammation. Cornea 2017; 36 (Suppl 1): S9-S14.
67. Madeira NG, Sogayar MI. Prevalencia de *Demodex folliculorum* e *Demodex* brevis em uma amostra da população de botucatu, São Paulo, Brasil. Rev Soc Bras Med Trop 1993; 26 (4): 221-224.
68. Mastrotta KM. Method to identify *Demodex* in the eyelash follicle without epilation. Optom Vis Sci 2013; 90 (6): e172-e174.
69. McMahon FW, Gallagher C, O'Reilly N, Clynes M, O'Sullivan F, Kavanagh K. Exposure of a corneal epithelial cell line (hTCEpi) to *Demodex*-associated *Bacillus* proteins results in an inflammatory response. Invest Ophthalmol Vis Sci 2014; 55 (10): 7019-7028.
70. Messaoud R, El Fekih L, Mahmoud A, Ben Amor H, Bannour R, Doan S, Khairallah M. Improvement in ocular symptoms and signs in patients with *Demodex* anterior blepharitis using a novel terpinen-4-ol (2.5%) and hyaluronic acid (0.2%) cleansing wipe. Clin Ophthalmol. 2019;13 1043-1054.

71. Morkin MI, Hamrah P. Man presents with persistent foreign body sensation and swollen eyelids. Exam findings include anterior and posterior blepharitis, lid margin telangiectasia and collarettes. *Ocul Surg News US* 2016; 34 (13 Suppl.): 1-6.
72. Muntz A, Purslow C, Wolffsohn JS, Craig JP. Improved Demodex Diagnosis in the Clinical Setting Using a Novel in Situ Technique. *Cont Lens Anterior Eye* 2019; S1367-0484(19)30183-3.
73. Nicholls SG, Oakley CL, Tan A, Vote BJ. *Demodex* species in human ocular disease: new clinicopathological aspects. *Int Ophthalmol* 2017; 37 (1): 303-312.
74. Norn MS. *Demodex folliculorum*. Incidence and possible pathogenic role in the human eyelid. *Acta Ophthalmol Suppl* 1970; 108 (III): 31-42.
75. Nutting WB, Green AC. Pathogenesis associated with hair follicle mites (*Demodex* spp.) in Australian Aborigines. *Br J Dermatol* 1976; 94 (3): 307-312.
76. O'Reilly N, Gallagher C, Reddy KK, Clynes M, O'Sullivan F, Kavanagh K. *Demodex*-associated *Bacillus* proteins induce an aberrant wound healing response in a corneal epithelial cell line: possible implications for corneal ulcer formation in ocular rosacea. *Invest Ophthalmol Vis Sci* 2012; 53 (6): 3250-3259.
77. O'Reilly N, Bergin D, Reeves EP, McElvaney NG, Kavanagh K. *Demodex*-associated bacterial proteins induce neutrophil activation. *Br J Dermatol* 2012; 166 (4): 753-760.
78. Pallotta S, Cianchini G, Martelloni E, Ferranti G, Girardelli CR, Di LG, Puddu P. Unilateral demodicidosis. *Eur J Dermatol* 1998; 8 (3): 191-192.
79. Parodi A, Drago F, Paolino S, Cozzani E, Gallo R. Treatment of rosacea. *Ann Dermatol Venereol* 2011; 138 (Suppl 3): S211-S214.
80. Persi A, Rebora A. Metronidazole and *Demodex folliculorum*. *Acta Derm Venereol* 1981; 61 (2): 182-183.
81. Post CF, Juhlin E. *Demodex folliculorum* and blepharitis. *Arch Dermatol* 1963; 88: 298-302.
82. Qiu TY, Yeo S, Tong L. Satisfaction and convenience of using terpenoid-impregnated eyelid wipes and teaching method in people without blepharitis. *Clin Ophthalmol* 2018; 12: 91-98.
83. Randon M, Liang H, El HM, Tahiri R, Batellier L, Denoyer A, Labbe A, Baudouin C. In vivo confocal microscopy as a novel and reliable tool for the diagnosis of *Demodex* eyelid infestation. *Br J Ophthalmol* 2015; 99 (3): 336-341.
84. Raoufinejad K, Mansouri P, Rajabi M, Naraghi Z, Jebraeili R. Efficacy and safety of permethrin 5% topical gel vs. placebo for rosacea: a double-blind randomized controlled clinical trial. *J Eur Acad Dermatol Venereol* 2016; 30 (12): 2105-2117.
85. Rather PA, Hassan I. Human *Demodex* mite: the versatile mite of dermatological importance. *Indian J Dermatol* 2014; 59 (1): 60-66.
86. Rodriguez AE, Ferrer C, Alio JL. *Demodex* y blefaritis crónica. *Arch Soc Esp Oftalmol* 2005; 80 (11): 635-642.
87. Ruffli T, Mumcuoglu Y. The hair follicle mites *Demodex folliculorum* and *Demodex brevis*: biology and medical importance. A review. *Dermatologica* 1981; 162 (1): 1-11.

88. Rusiecka-Ziolkowska J, Nokiel M, Fleischer M. *Demodex* - an old pathogen or a new one? Adv Clin Exp Med 2014; 23 (2): 295-298.
89. Rykov S, Petrenko O, Shargorodskaya I. Modern aspects of *Demodex* blepharitis treatment. Ever. Nice, France, October 5-8, 2016. 2016; Abstract S072.
90. Rynerson JM, Perry HD. DEBS - a unification theory for dry eye and blepharitis. Clin Ophthalmol 2016; 10: 2455-2467.
91. Salem DA, El-Shazly A, Nabih N, El-Bayoumy Y, Saleh S. Evaluation of the efficacy of oral ivermectin in comparison with ivermectin-metronidazole combined therapy in the treatment of ocular and skin lesions of *Demodex folliculorum*. Int J Infect Dis 2013; 17 (5): e343-e347.
92. Sattler EC, Hoffmann VS, Ruzicka T, Braunmuhl TV, Berking C. Reflectance confocal microscopy for monitoring the density of *Demodex* mites in patients with rosacea before and after treatment. Br J Dermatol 2015; 173 (1): 69-75.
93. Schachter C. Pediatric *Demodex*, a case series. AAOPT - American Academy of Optometry Annual Meeting. Seattle, USA, October 23-26, 2013. 2013; Abstract 135822.
94. Schaller M, Sander CA, Plewig G. *Demodex* abscesses: clinical and therapeutic challenges. J Am Acad Dermatol 2003; 49 (5 Suppl): S272-S274.
95. Schaller M, Gonser L, Belge K, Braunsdorf C, Nordin R, Scheu A, Borelli C. Dual anti-inflammatory and anti-parasitic action of topical ivermectin 1% in papulopustular rosacea. J Eur Acad Dermatol Venereol 2017; 31 (11): 1907-1911.
96. Schear MJ, Milman T, Steiner T, Shih C, Udell IJ, Steiner A. The Association of *Demodex* with Chalazia: A Histopathologic Study of the Eyelid. Ophthalmic Plast Reconstr Surg 2016; 32 (4): 275-278.
97. Sharma YK, Gupta A. Human *Demodex* mite: the versatile mite of dermatological importance. Indian J Dermatol 2014; 59 (3): 302.
98. Shelley WB, Shelley ED, Burmeister V. Unilateral demodectic rosacea. J Am Acad Dermatol 1989; 20 (5 Pt 2): 915-917.
99. Sibenge S, Gawkrödger DJ. Rosacea: a study of clinical patterns, blood flow, and the role of *Demodex folliculorum*. J Am Acad Dermatol 1992; 26 (4): 590-593.
100. Sung J, Wang MTM, Lee SH, Cheung IMY, Ismail S, Sherwin T, Craig JP. Randomized double-masked trial of eyelid cleansing treatments for blepharitis. Ocul Surf 2018; 16 (1): 77-83.
101. Szkaradkiewicz A, Chudzicka-Strugala I, Karpinski TM, Goslinska-Pawlowska O, Tulecka T, Chudzicki W, Szkaradkiewicz AK, Zaba R. *Bacillus oleronius* and *Demodex* mite infestation in patients with chronic blepharitis. Clin Microbiol Infect 2012; 18 (10): 1020-1025.
102. Tarkowski W, Owczynska M, Blaszczyk-Tyszka A, Mlocicki D. *Demodex* mites as potential etiological factor in chalazion - a study in Poland. Acta Parasitol 2015; 60 (4): 777-783.
103. Tarkowski W, Moneta-Wielgos J, Mlocicki D. *Demodex* sp. as a Potential Cause of the Abandonment of Soft Contact Lenses by Their Existing Users. Biomed Res Int 2015; 2015: Abstract 259109.
104. Tehrani S, Tizmaghz A, Shabestanipour G. The *Demodex* mites and their relation with seborrheic and atopic Dermatitis. Asian Pac J Trop Med 2014; 7 (S1): S82-S84.
105. Tighe S, Gao YY, Tseng SC. Terpinen-4-ol is the Most Active Ingredient of Tea Tree Oil to Kill *Demodex* Mites. Transl Vis Sci Technol 2013; 2 (7): 2.

106. Tilki E, Zeytun E, Dogan S. Prevalence and Density of *Demodex folliculorum* and *Demodex brevis* (Acari: Demodicidae) in Erzincan Province. *Turkiye Parazitolo Derg* 2017; 41 (2): 80-86.
107. Tsai YJ, Chung WC, Wang LC, Ju YT, Hong CL, Tsai YY, Li YH, Wu YL. The dog mite, *Demodex canis*: prevalence, fungal co-infection, reactions to light, and hair follicle apoptosis. *J Insect Sci* 2011; 11: 76.
108. Vargas-Arzola J, Reyes-Velasco L, Segura-Salvador A, Marquez-Navarro A, Diaz-Chiguer DL, Noguera-Torres B. Prevalence of *Demodex* mites in eyelashes among people of Oaxaca, Mexico. *Acta Microbiol Immunol Hung* 2012; 59 (2): 257-262.
109. Wesolowska M, Knysz B, Reich A, Blazejewska D, Czarnecki M, Gladysz A, Pozowski A, Misiuk-Hojlo M. Prevalence of *Demodex* spp. in eyelash follicles in different populations. *Arch Med Sci* 2014; 10 (2): 319-324.
110. Yam JC, Tang BS, Chan TM, Cheng AC. Ocular demodicidosis as a risk factor of adult recurrent chalazion. *Eur J Ophthalmol* 2014; 24 (2): 159-163.
111. Zhao YE, Wu LP, Hu L, Xu JR. Association of blepharitis with *Demodex*: a meta-analysis. *Ophthalmic Epidemiol* 2012; 19 (2): 95-102.
112. Zhao YE, Peng Y, Wang XL, Wu LP, Wang M, Yan HL, Xiao SX. Facial dermatosis associated with *Demodex*: a case-control study. *J Zhejiang Univ Sci B* 2011; 12 (12): 1008-1015.
113. Zhao YE, Wu LP, Peng Y, Cheng H. Retrospective analysis of the association between *Demodex* infestation and rosacea. *Arch Dermatol* 2010; 146 (8): 896-902.

## INTERNAL REFERENCE

---

Clinical Evaluation Report - Project Number: FR001049-0002 - Blephademo<sup>®</sup> - NAMS - 22 February 2018.







# *Demodex* in ophthalmology

OVERVIEW OF THE LATEST EVIDENCE



Collection Librairie Médicale Théa



Laboratoires Théa  
12 Rue Louis Blériot - ZI du Brézet  
63017 Clermont-Ferrand cedex 2 - France  
Tel. +33 (0)4 73 98 14 36 - Fax +33 (0)4 73 98 14 38  
[www.laboratoires-thea.com](http://www.laboratoires-thea.com)